

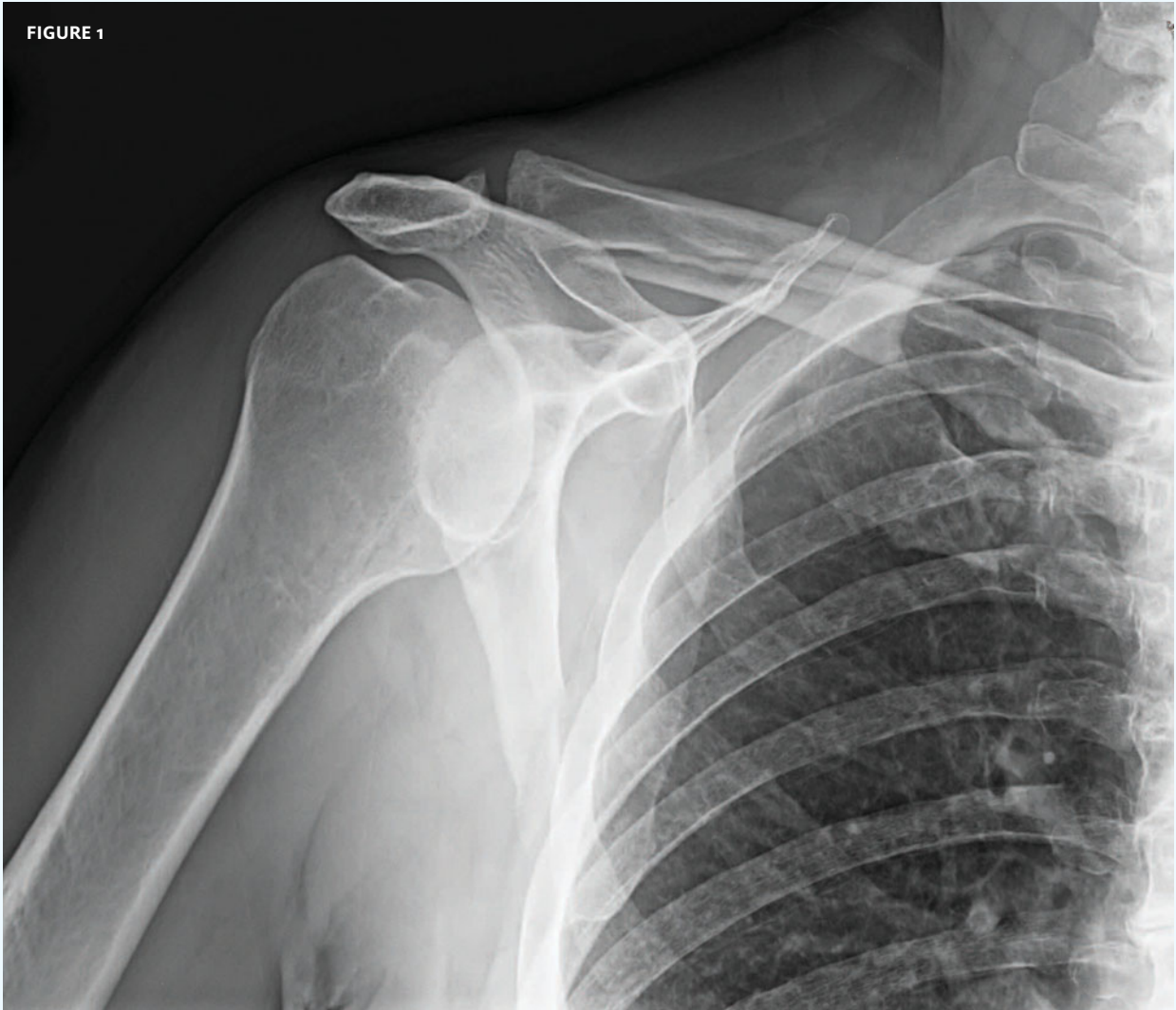


INSIGHTS IN IMAGES  
CLINICAL CHALLENGE

In each issue, *JUCM* will challenge your diagnostic acumen with a glimpse of x-rays, electrocardiograms, and photographs of conditions that real urgent care patients have presented with.

If you would like to submit a case for consideration, please e-mail the relevant materials and presenting information to [editor@jucm.com](mailto:editor@jucm.com).

FIGURE 1



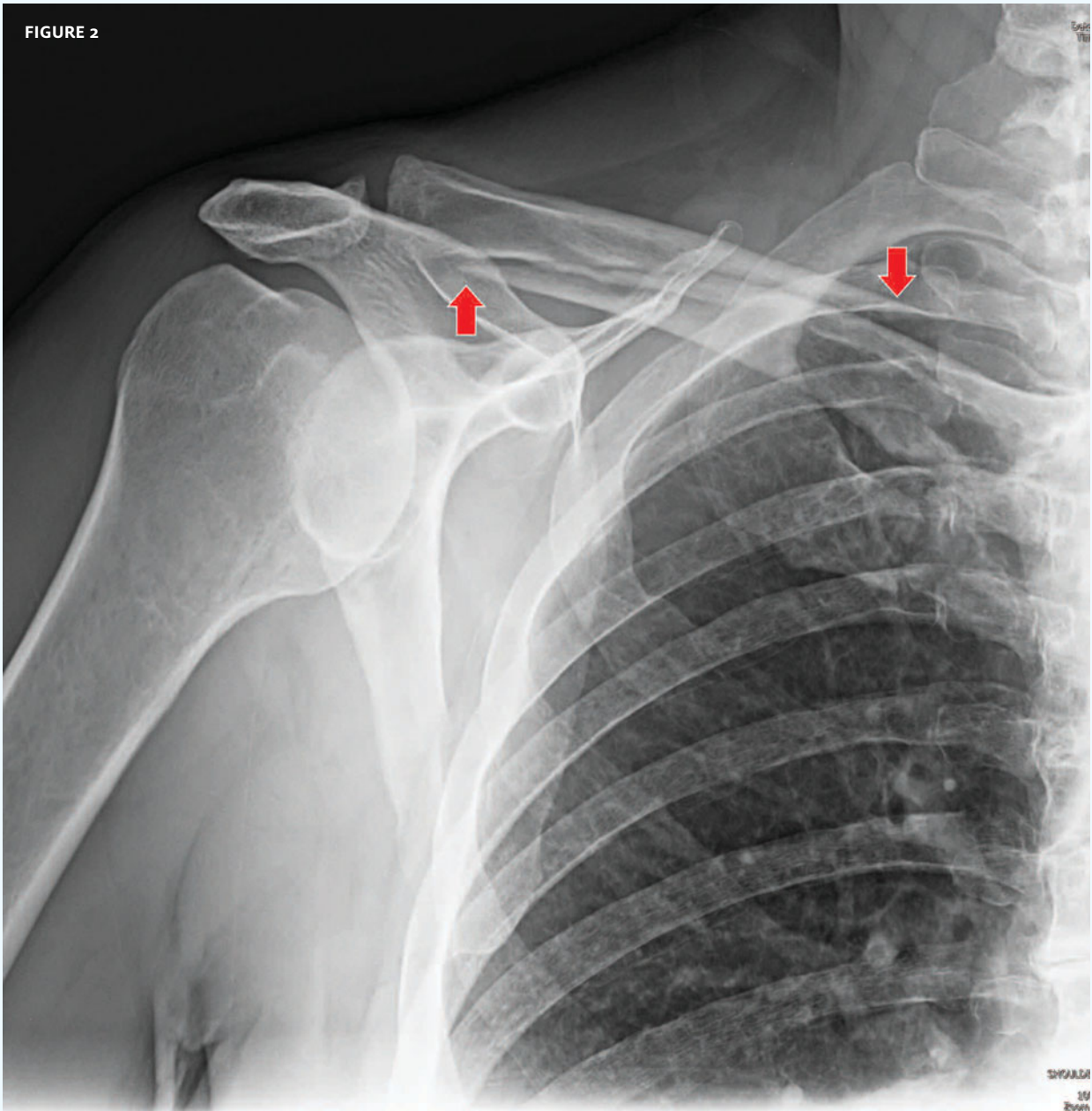
This x-ray was taken on a 72-year-old man who presented to urgent care after falling off a step stool while trimming branches. He landed directly on his left shoulder and was unable to lift his arm over his head due to severe pain. He thought his shoulder was dislocated.

View the image taken (**Figure 1**) and consider what your diagnosis would be.

Resolution of the case is described on the next page.

THE RESOLUTION

FIGURE 2



Diagnosis: The x-ray reveals a minimally displaced transverse clavicle fracture. This is an unusual clavicle fracture in that it cannot be classified into the “third system” of medial, middle, and lateral clavicle fractures. This fracture is actually lateral and middle (arrows). As there was no compromise to the skin and no severe deformity, no specific treatment was required. The patient was placed in a sling and advised to follow up with his primary care physician.

*Acknowledgement: Case presented by Tracey Quail Davidoff, MD, an urgent care physician at Accelcare Medical Urgent Care and Urgent Care by Lifetime Health in Rochester, NY.*