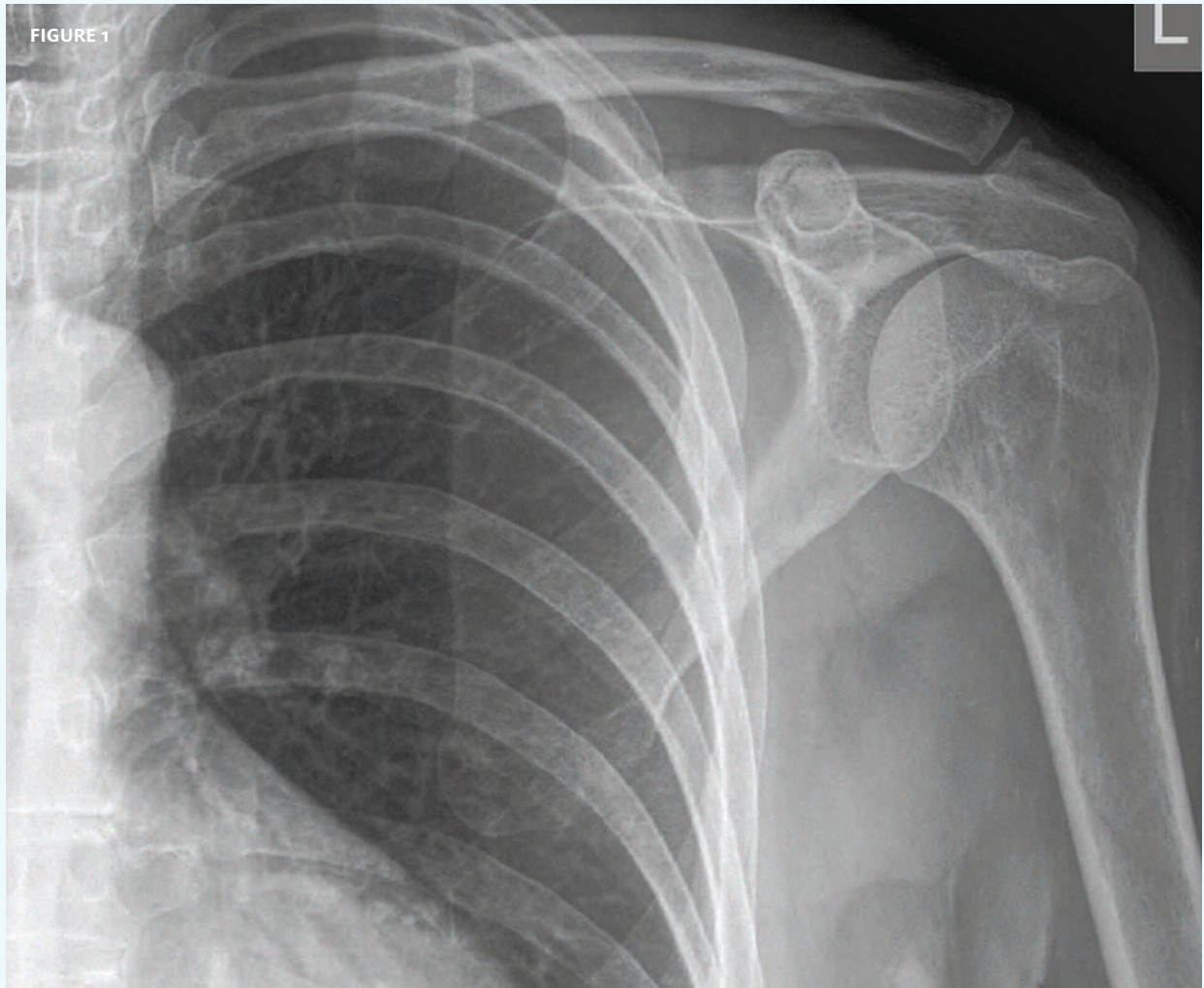




In each issue, *JUCM* will challenge your diagnostic acumen with a glimpse of x-rays, electrocardiograms, and photographs of conditions that real urgent care patients have presented with.

If you would like to submit a case for consideration, please email the relevant materials and presenting information to editor@jucm.com.

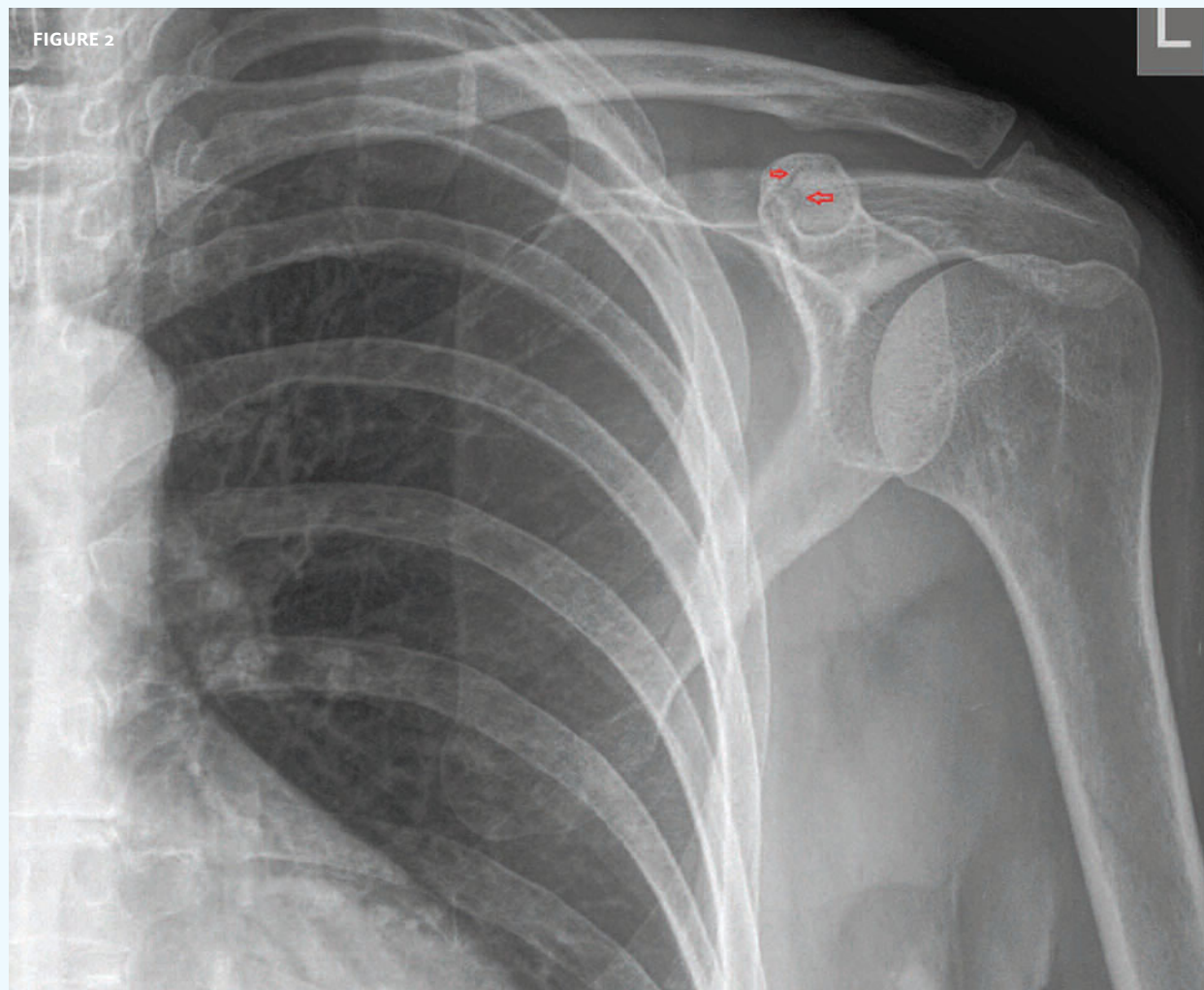


The patient, a 67-year-old man, presented after a blow to his left shoulder.

View the image taken (**Figure 1**) and consider what your diagnosis would be.

Resolution of the case is described on the next page.

THE RESOLUTION

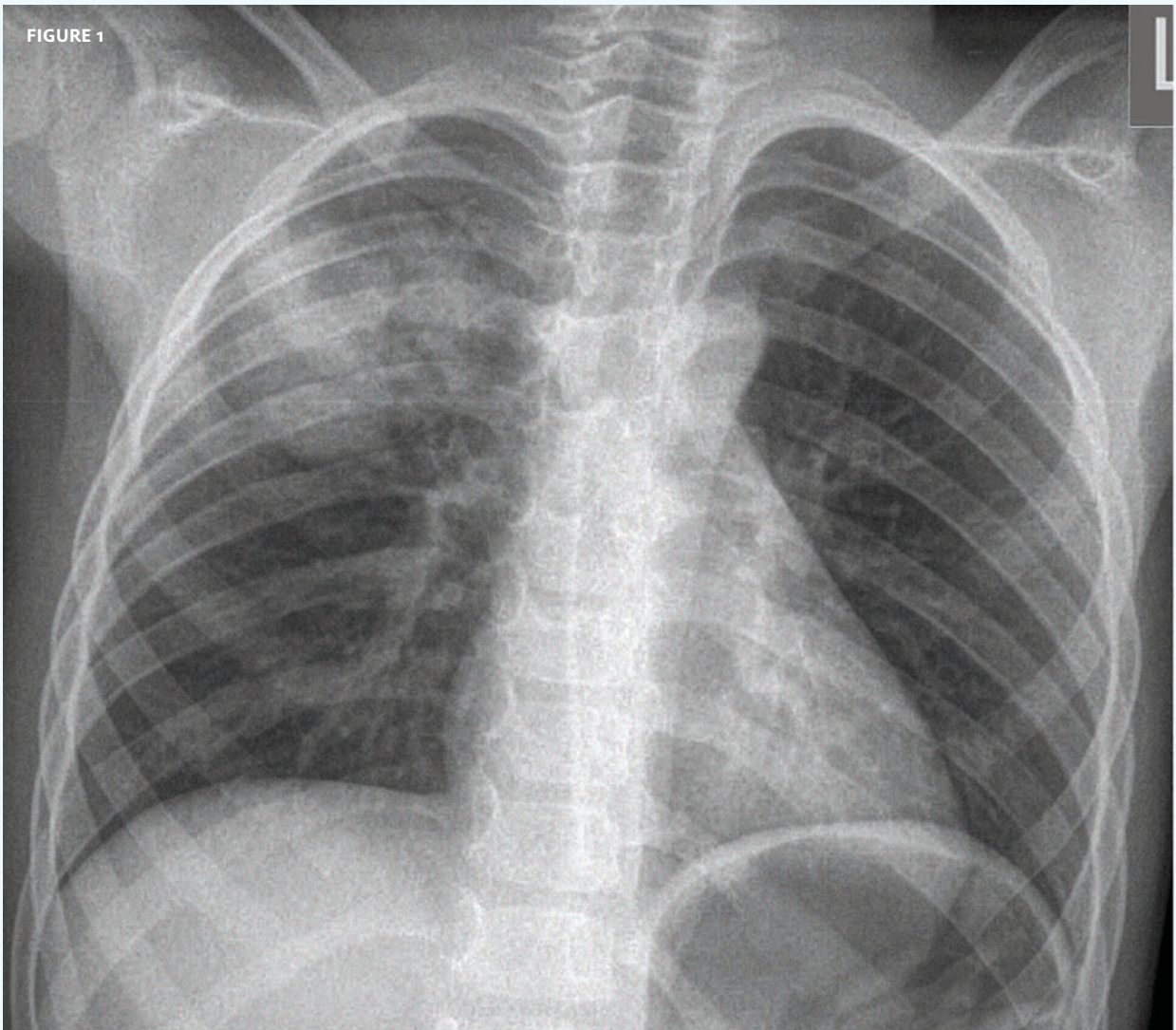


Diagnosis: The x-ray reveals a fracture of the acromion (arrows). A sling and follow up with orthopedics are appropriate for this patient.

Acknowledgement: Case presented by Nahum Kovalski, BSc, MDCM, Terem Emergency Medical Centers, Jerusalem, Israel.



FIGURE 1



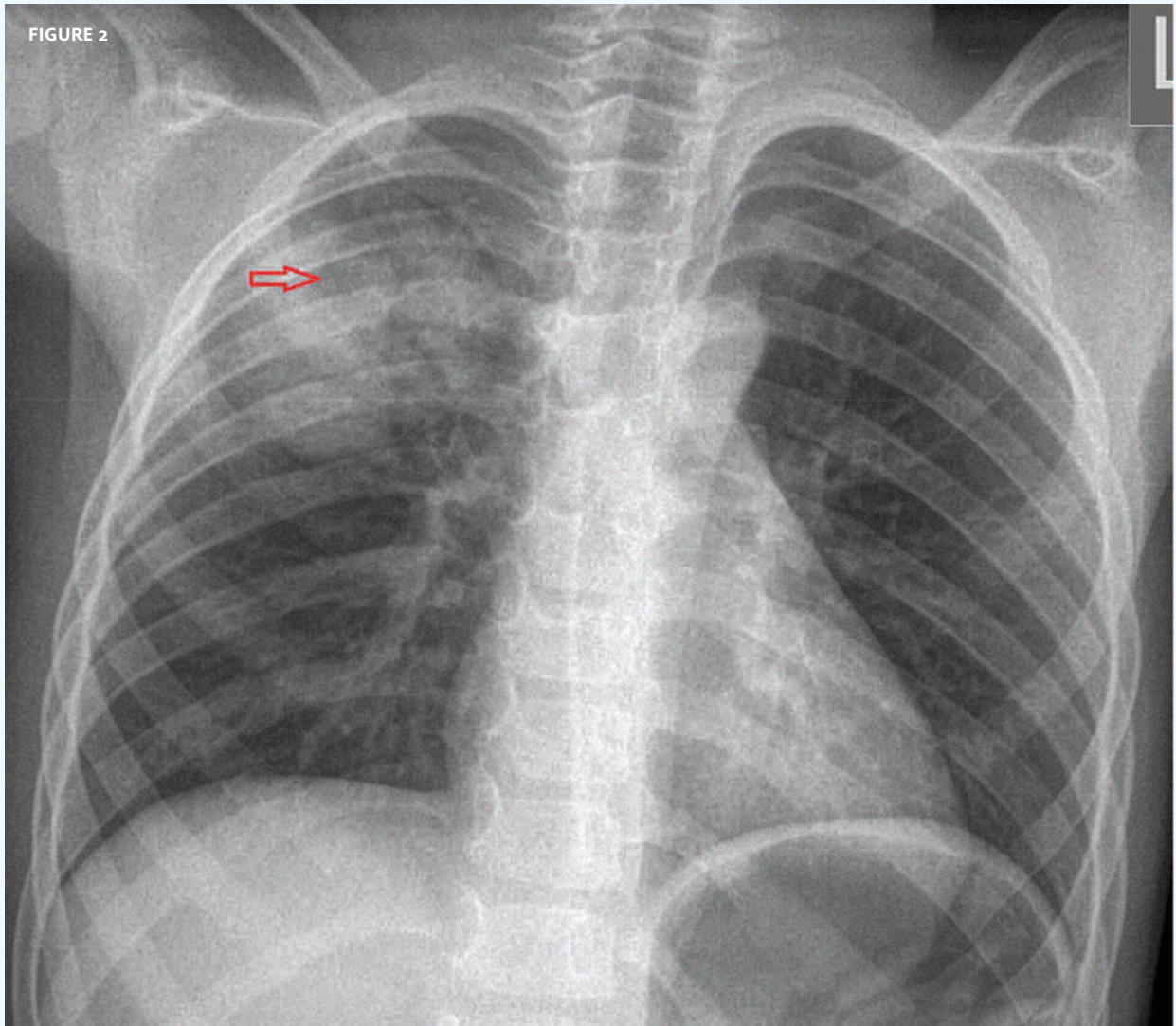
The patient, a 6-year-old girl, presented with a fever and cough.

View the image taken (**Figure 1**) and consider what your diagnosis would be.

Resolution of the case is described on the next page.

THE RESOLUTION

FIGURE 2



Diagnosis: The x-ray reveals consolidation in the right upper lobe and within the consolidation, there is an opacity (arrow). That does not necessarily mean that an abscess is forming but the patient should be followed closely.

Acknowledgement: Case presented by Nahum Kovalski, BSc, MDCM, Terem Emergency Medical Centers, Jerusalem, Israel.