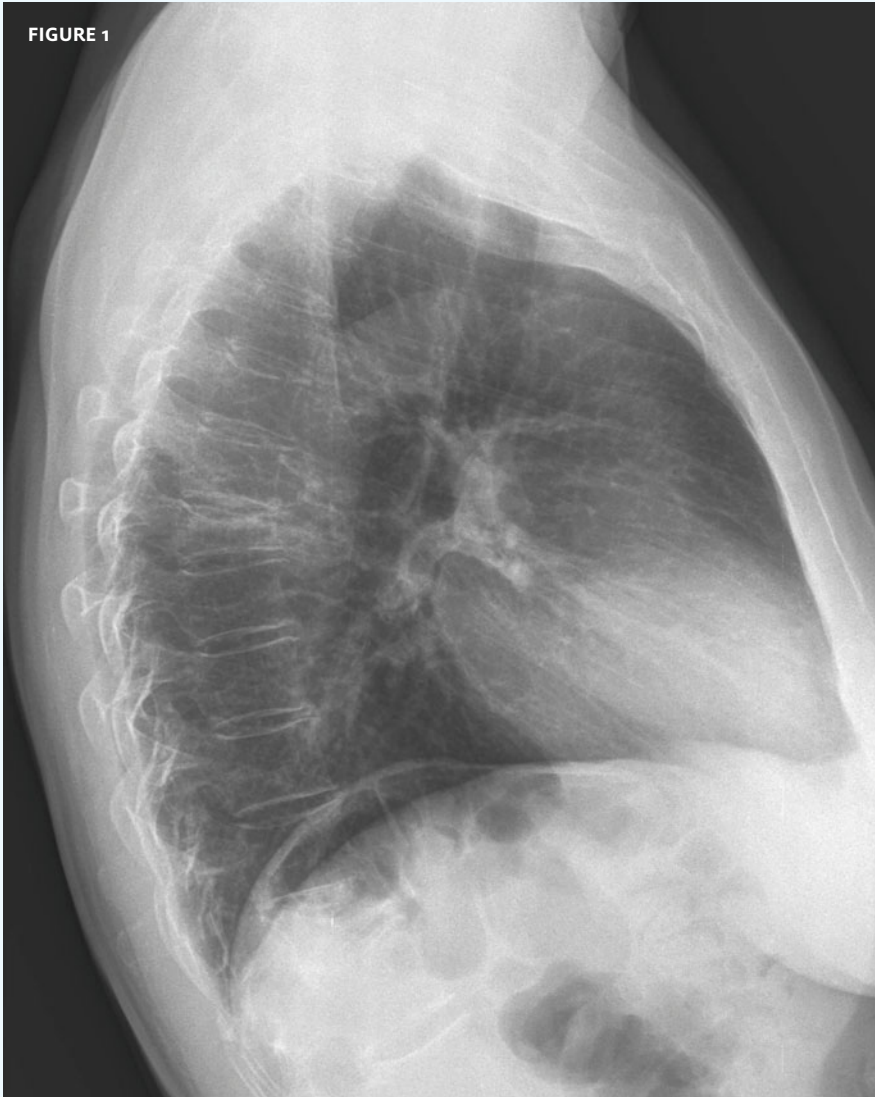

In each issue, *JUCM* will challenge your diagnostic acumen with a glimpse of x-rays, electrocardiograms, and photographs of conditions that real urgent care patients have presented with.

If you would like to submit a case for consideration, please email the relevant materials and presenting information to editor@jucm.com.

FIGURE 1



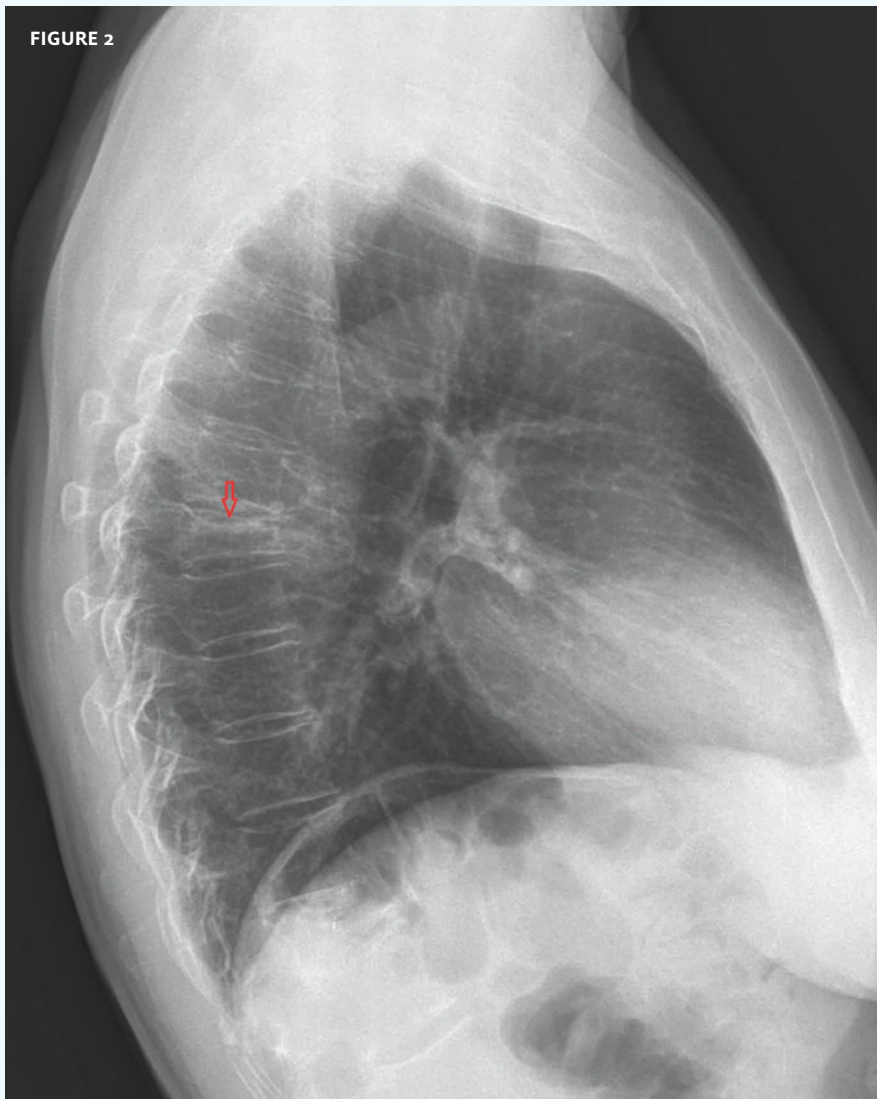The patient, a 53-year-old man, presented with acute back pain after a fall.

View the image taken (**Figure 1**) and consider what your diagnosis would be.

Resolution of the case is described on the next page.

THE RESOLUTION

FIGURE 2

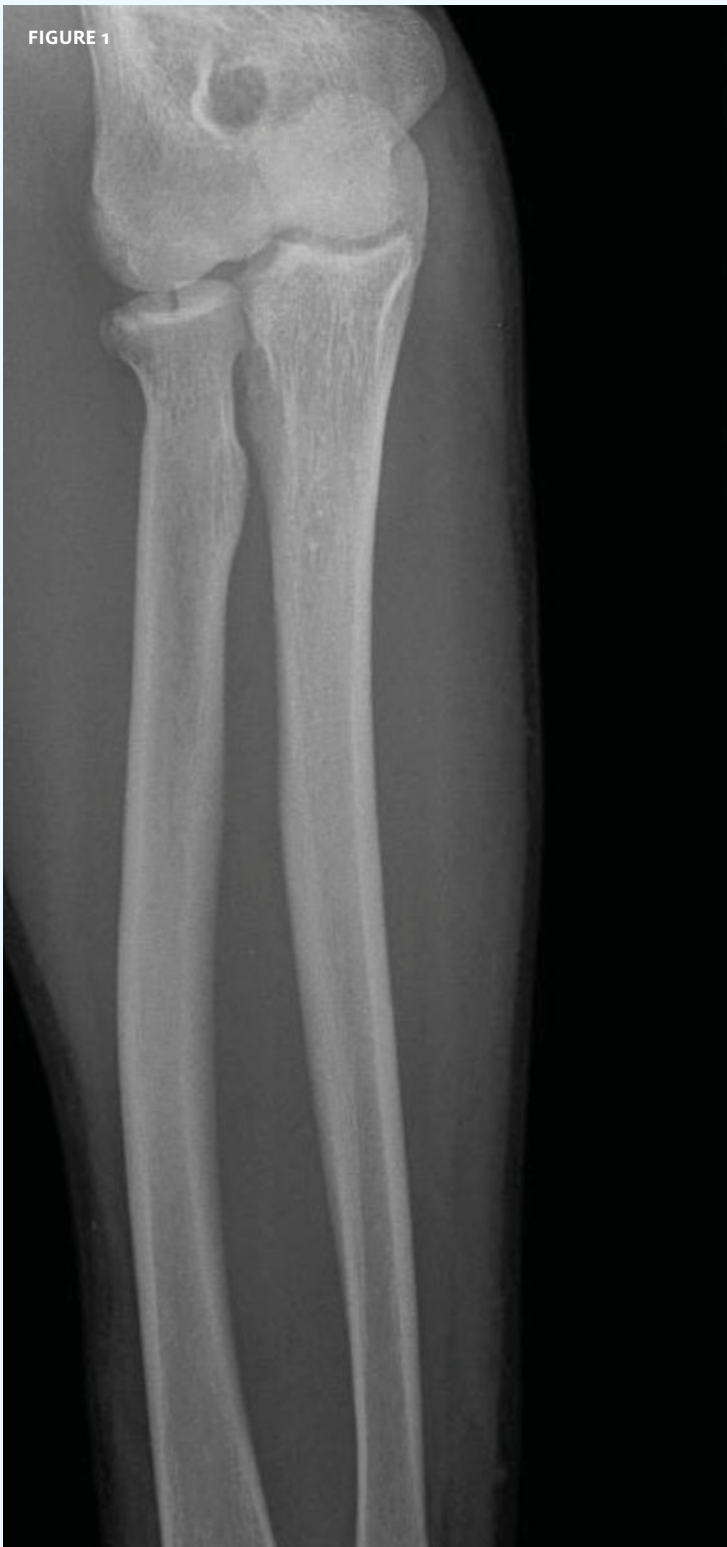

Diagnosis: The x-ray reveals a significant compression fracture of the thoracic spine (arrow). This patient requires an orthopedics referral for immediate evaluation and treatment.

*Acknowledgement:
Case presented by
Nahum Kovalski, BSc, MDCM,
Terem Emergency Medical
Centers, Jerusalem, Israel.*




FIGURE 1



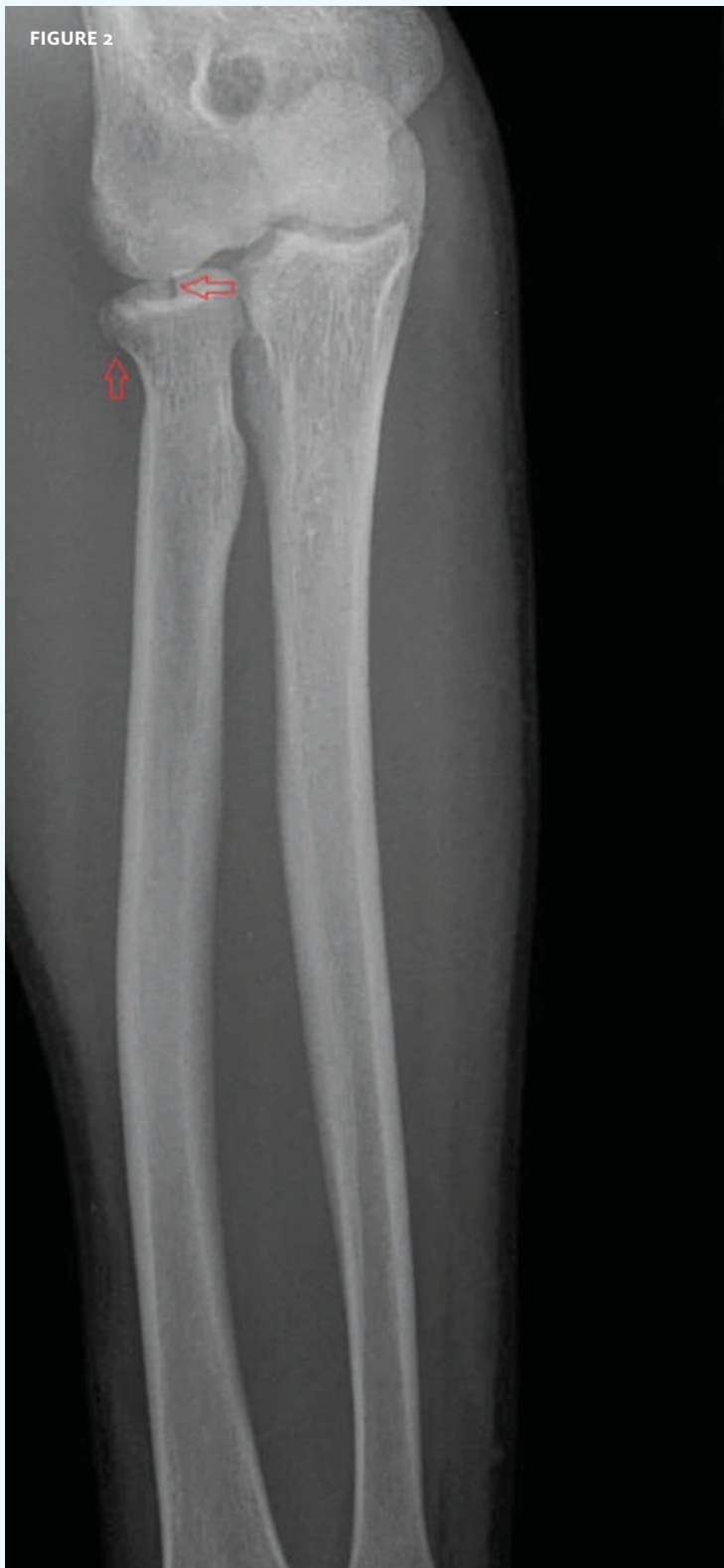This x-ray was taken on a 29-year-old man with a blow to his left elbow.

View the image taken (**Figure 1**) and consider what your diagnosis would be.

[Click here for the resolution of the case.](#)

THE RESOLUTION

FIGURE 2



Diagnosis: The x-ray reveals an intra-articular radial head fracture (arrows). A splint and follow up with an orthopedist are appropriate for this patient.

Acknowledgement:

Case presented by Nahum Kovalski, BSc, MDCM, Terem Emergency Medical Centers, Jerusalem, Israel.