

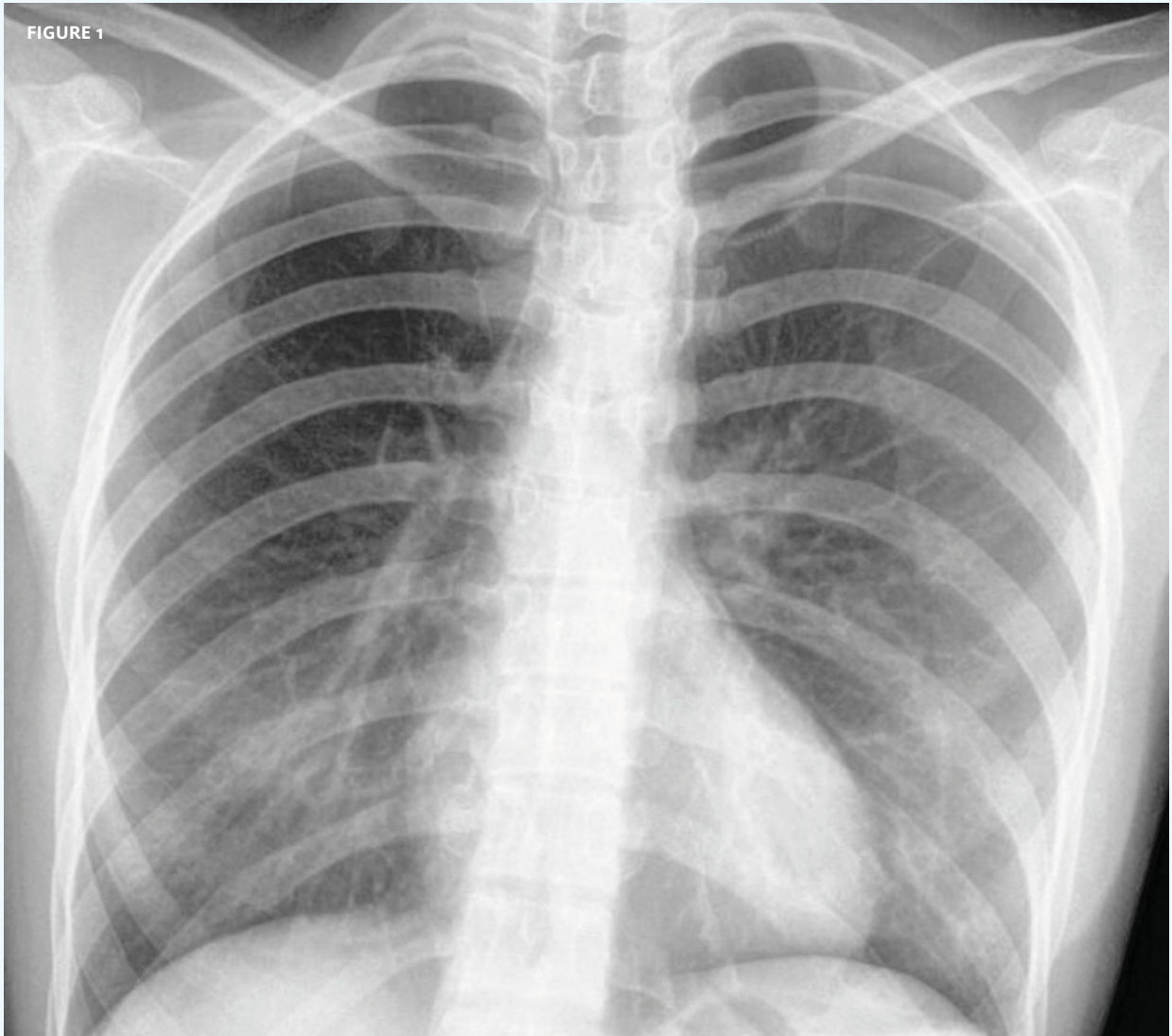


INSIGHTS IN IMAGES
CLINICAL CHALLENGE

In each issue, *JUCM* will challenge your diagnostic acumen with a glimpse of x-rays, electrocardiograms, and photographs of conditions that real urgent care patients have presented with.

If you would like to submit a case for consideration, please email the relevant materials and presenting information to editor@jucm.com.

FIGURE 1

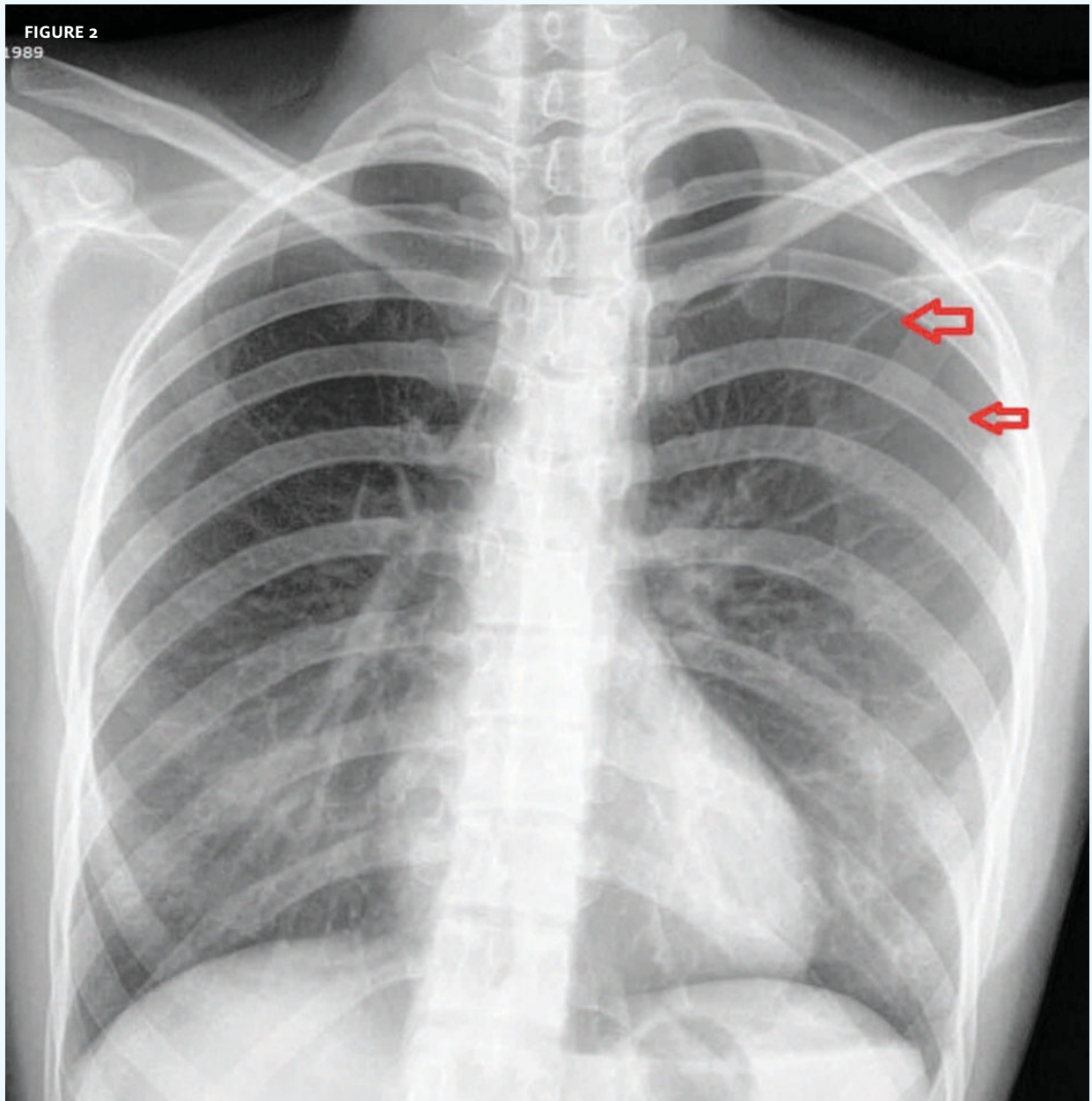


The patient, a 22-year-old woman, presented with a complaint of chest pain.

View the image taken (**Figure 1**) and consider what your diagnosis would be.

Resolution of the case is described on the next page.

THE RESOLUTION



Diagnosis: The x-ray reveals pneumothorax (arrows). Referral to a hospital is appropriate for this patient.

Acknowledgement: Case reprinted with permission from the Logical Images digital medical image library. For more information, visit <http://www.logicalimages.com>