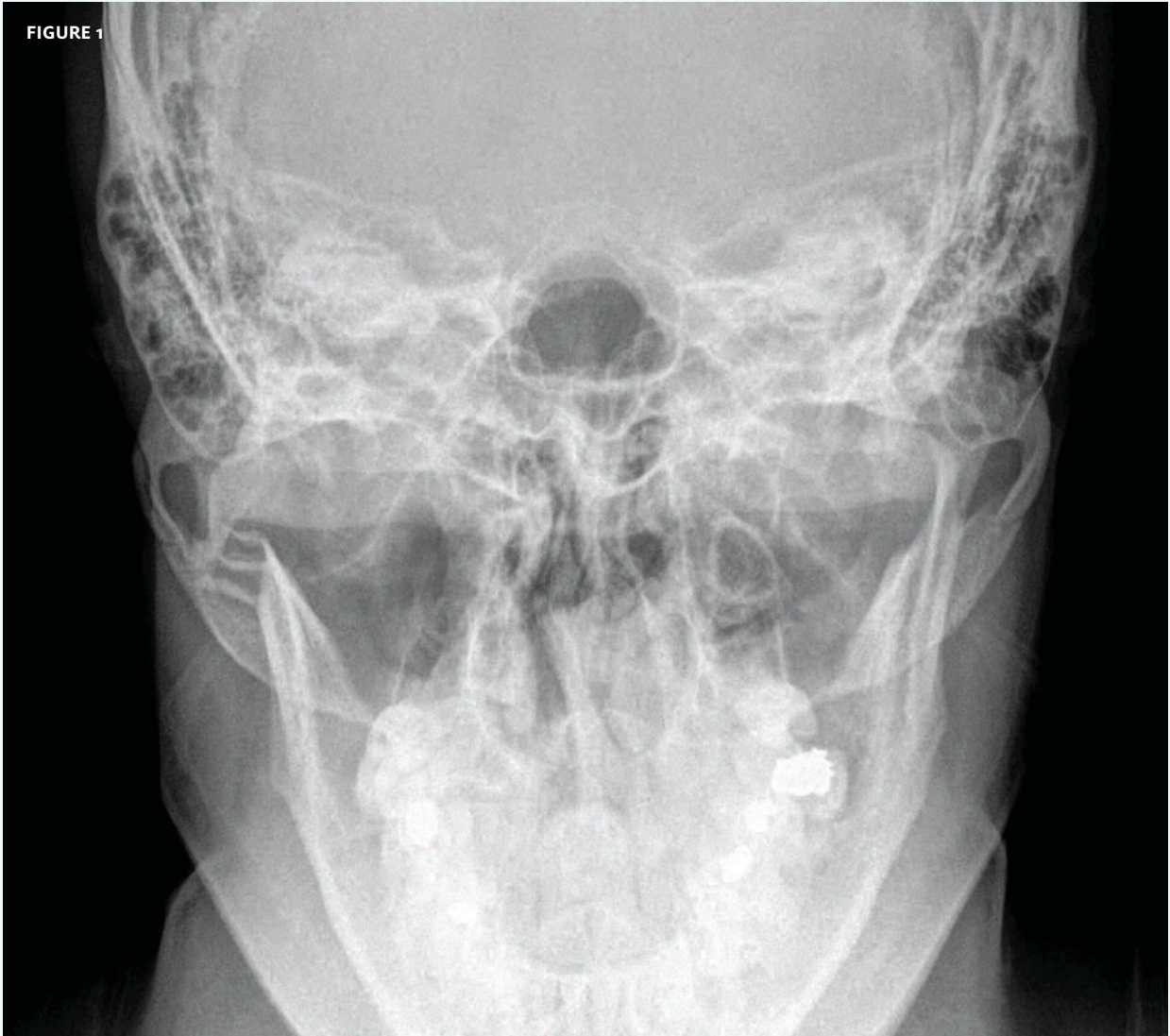

In each issue, *JUCM* will challenge your diagnostic acumen with a glimpse of x-rays, electrocardiograms, and photographs of dermatologic conditions that real urgent care patients have presented with.

If you would like to submit a case for consideration, please email the relevant materials and presenting information to editor@juqm.com.

FIGURE 1



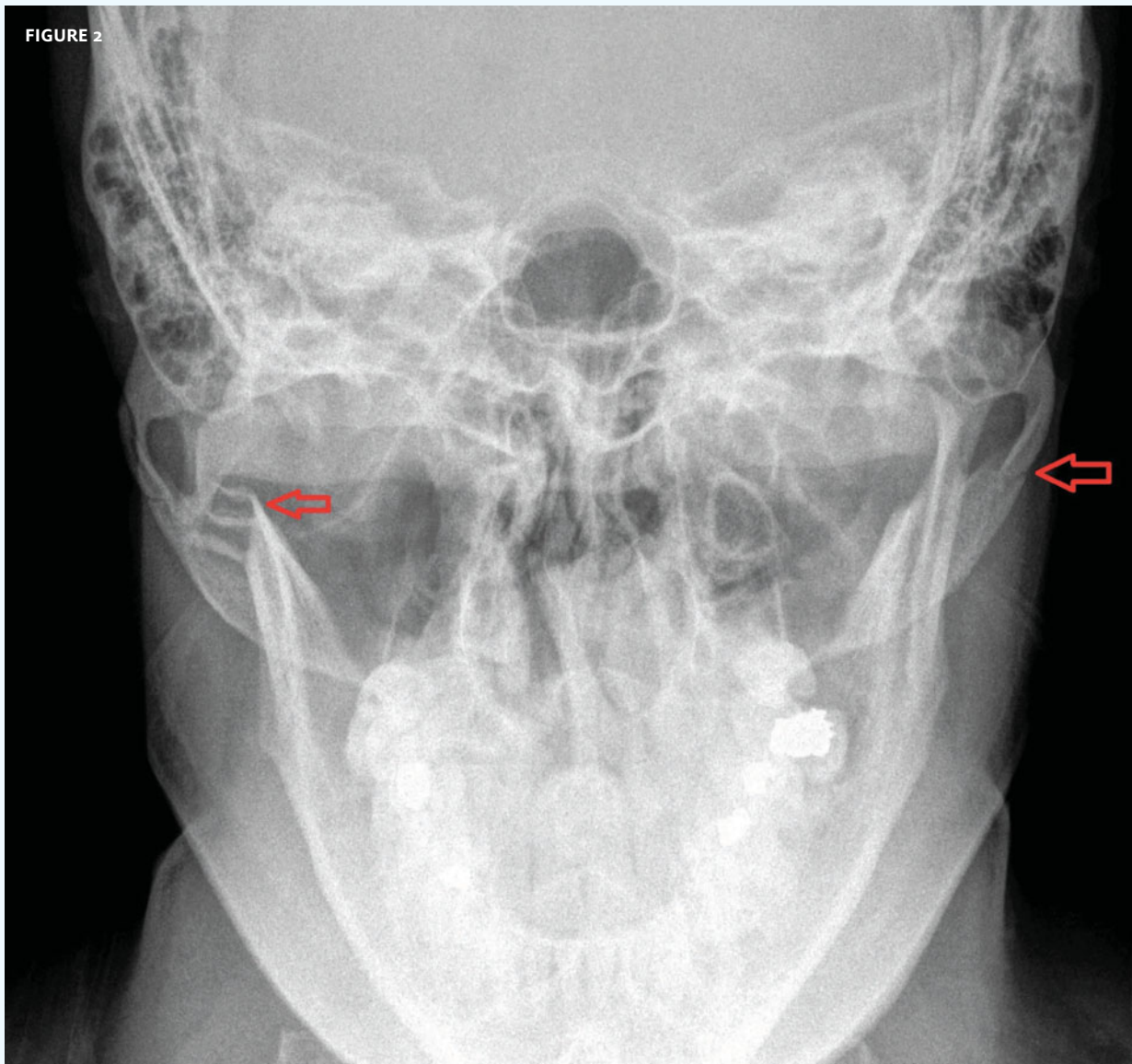
The patient, a 35-year-old male, presented after a blow to the face.

View the image taken (**Figure 1**) and consider what your diagnosis would be.

Resolution of the case is described on the next page.

THE RESOLUTION

FIGURE 2



Diagnosis: The x-ray reveals fractures of the mandible and zygoma (arrows). Referral to a hospital is appropriate for this patient.

Because of the complexity of facial anatomy and the risk of soft-tissue injury, computed tomography has largely replaced plain films for evaluating facial trauma.

Acknowledgement: Case presented by Nahum Kovalski, BSc, MDCM, Terem Emergency Medical Centers, Jerusalem, Israel.