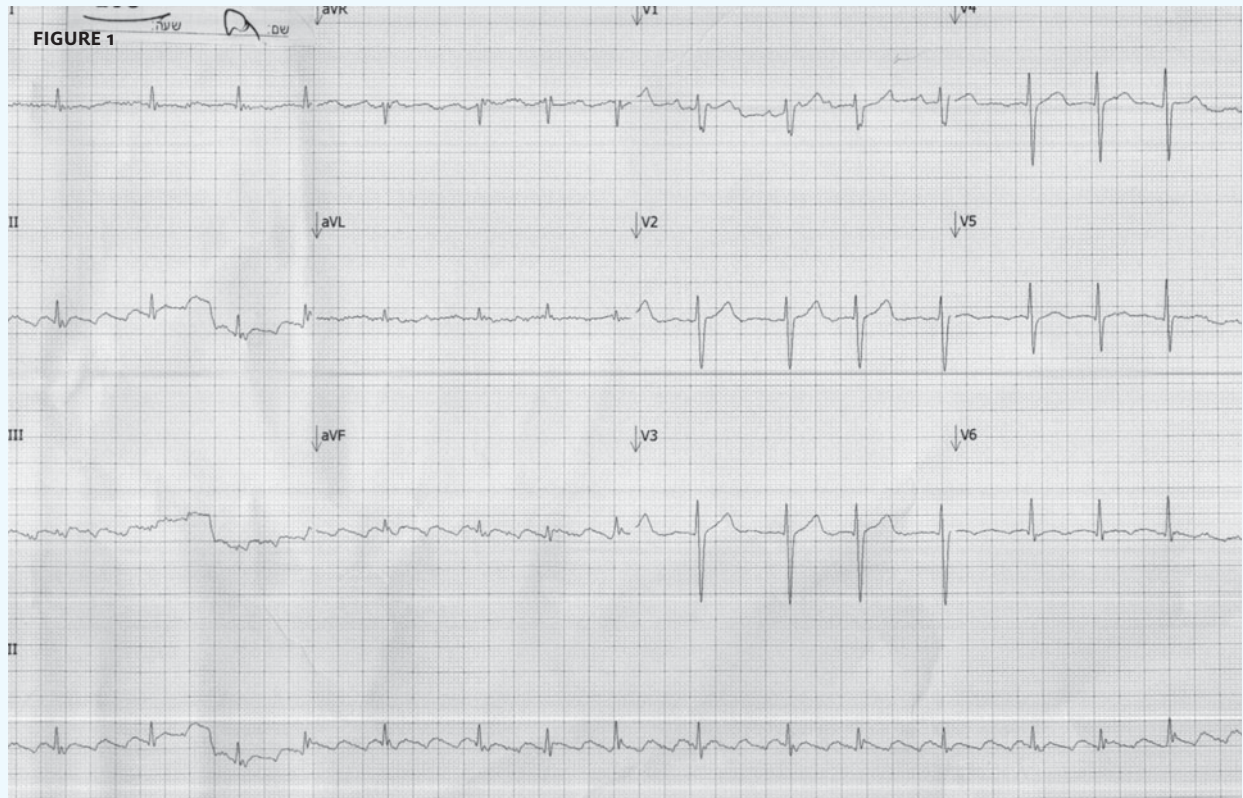


INSIGHTS IN IMAGES

CLINICAL CHALLENGE

In each issue, *JUCM* will challenge your diagnostic acumen with a glimpse of x-rays, electrocardiograms, and photographs of dermatologic conditions that real urgent care patients have presented with.

If you would like to submit a case for consideration, please email the relevant materials and presenting information to editor@jucm.com.

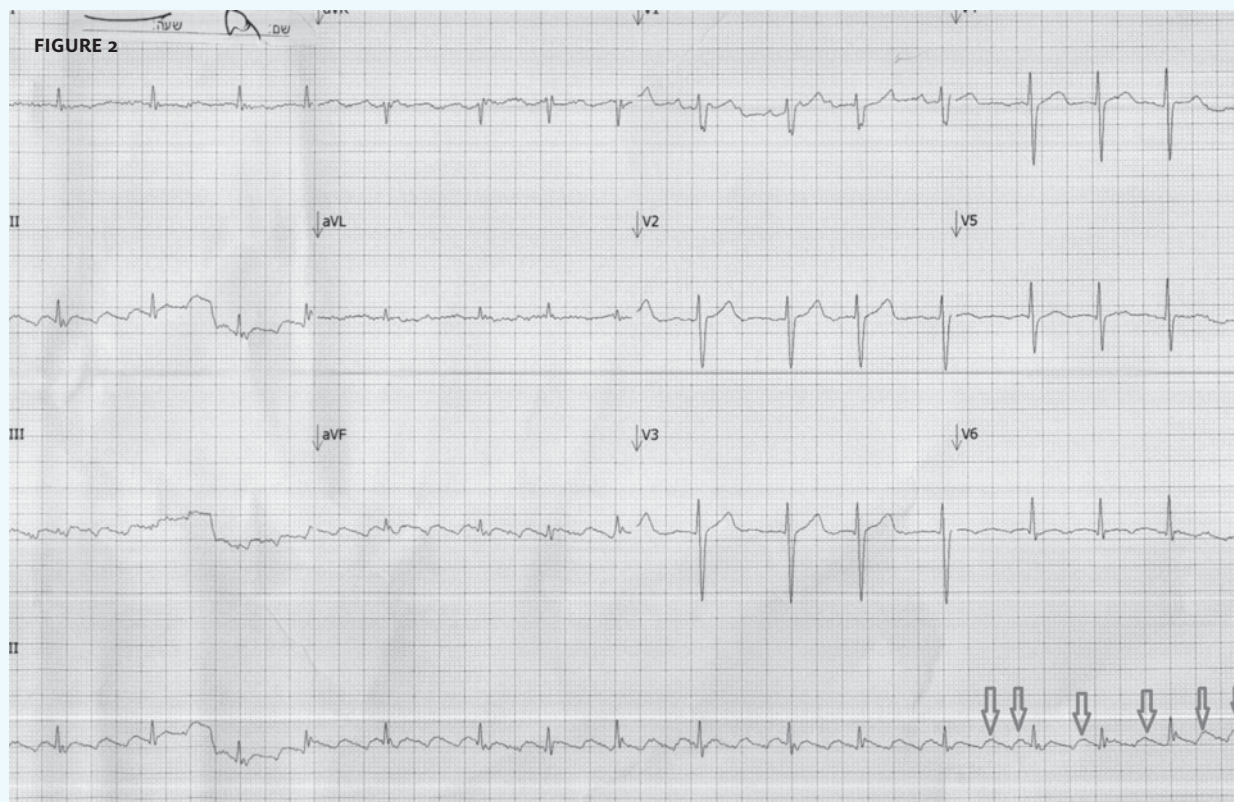


The patient, a 76-year-old male, presented with a complaint of palpitations.

View the image taken (**Figure 1**) and consider what your diagnosis would be.

Resolution of the case is described on the next page.

THE RESOLUTION



Diagnosis: The electrocardiogram reveals atrial flutter with block. The saw tooth pattern is consistent with atrial flutter at a much higher rate, but due to the block, a much slower ventricular rate.

Acknowledgement: Case presented by Nahum Kovalski, BSc, MDCM, Terem Emergency Medical Centers, Jerusalem, Israel.