



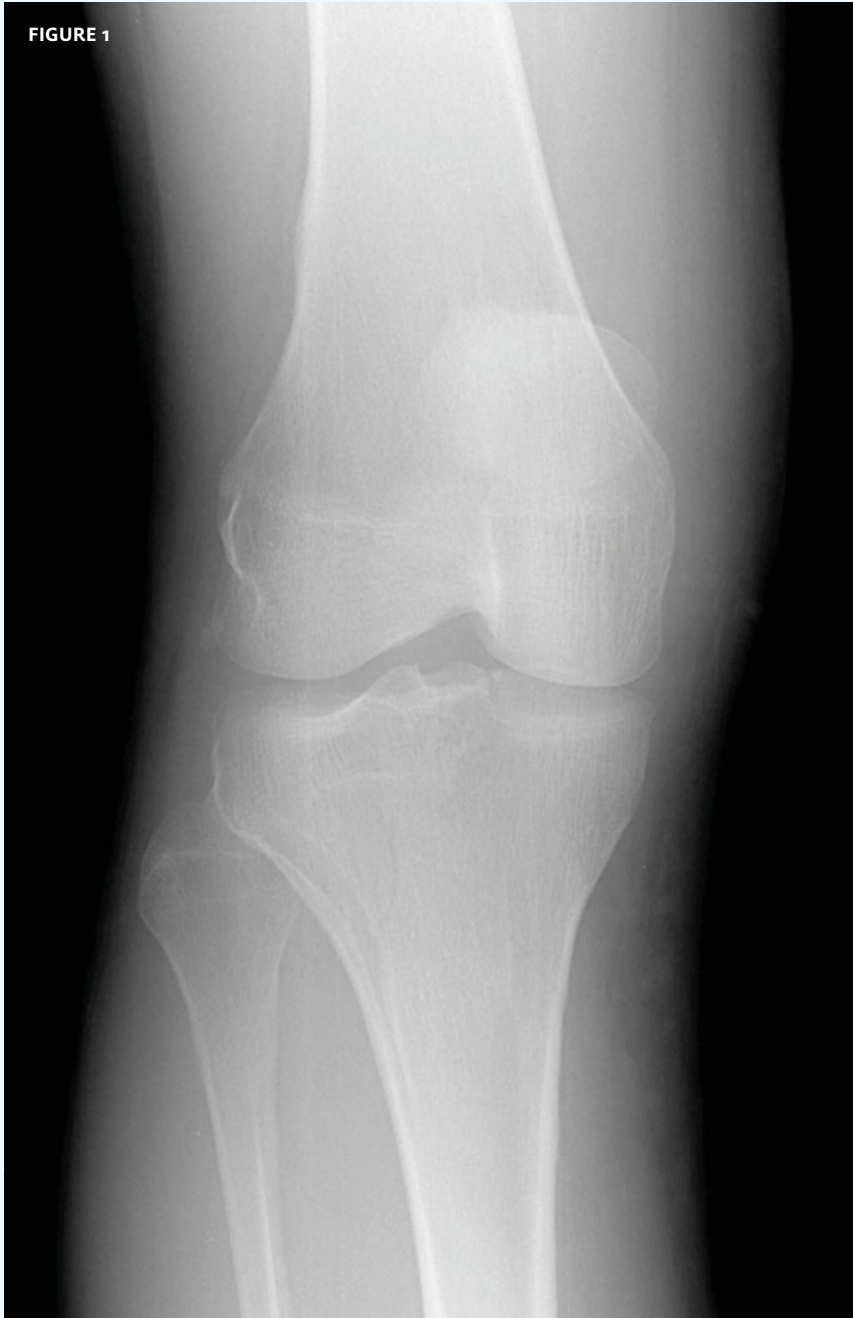INSIGHTS IN IMAGES

CLINICAL CHALLENGE

In each issue, *JUCM* will challenge your diagnostic acumen with a glimpse of x-rays, electrocardiograms, and photographs of dermatologic conditions that real urgent care patients have presented with.

If you would like to submit a case for consideration, please email the relevant materials and presenting information to editor@jucm.com.

FIGURE 1



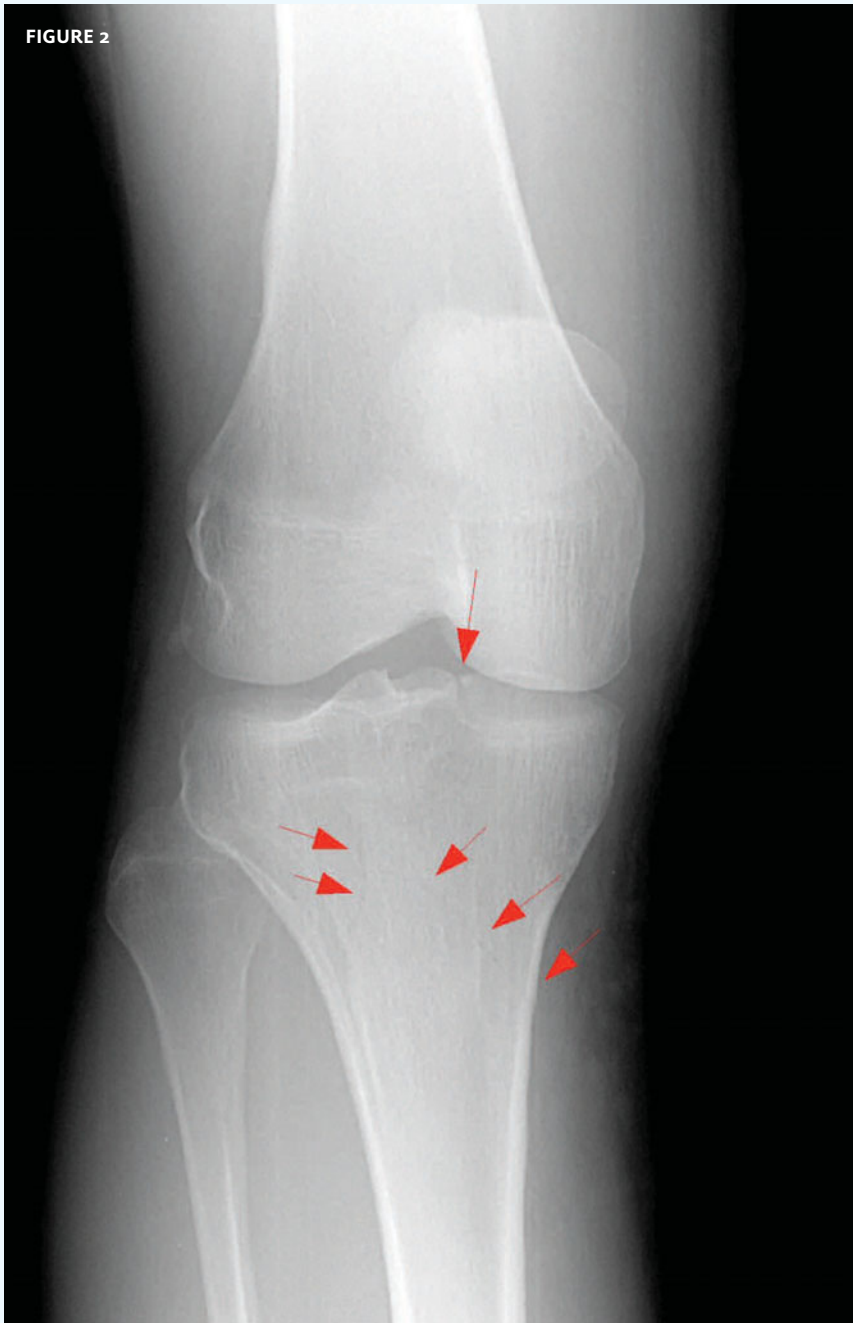
The patient, a 41-year-old male, was a construction worker who fell on his right knee. Because of the pain he opted to take a vacation from work for a week and not seek medical attention. Upon his return, he was still having pain and elected to be seek medical attention.

View the image taken (**Figure 1**) and consider what your diagnosis would be.

Resolution of the case is described on the next page.

THE RESOLUTION

FIGURE 2



Diagnosis: The x-ray reveals hairline fractures on both sides of the tibia as well as intra-articular extension. It is particularly important not to miss this significant tibial plateau fracture. If the fracture is missed and plateau depression occurs, it would have substantial negative consequences for future joint performance.

Acknowledgement: Case presented by Vina Maniquis, MD, site director, and John Koehler, MD, Chief Medical Officer, both of Physicians Immediate Care, Chicago, IL.