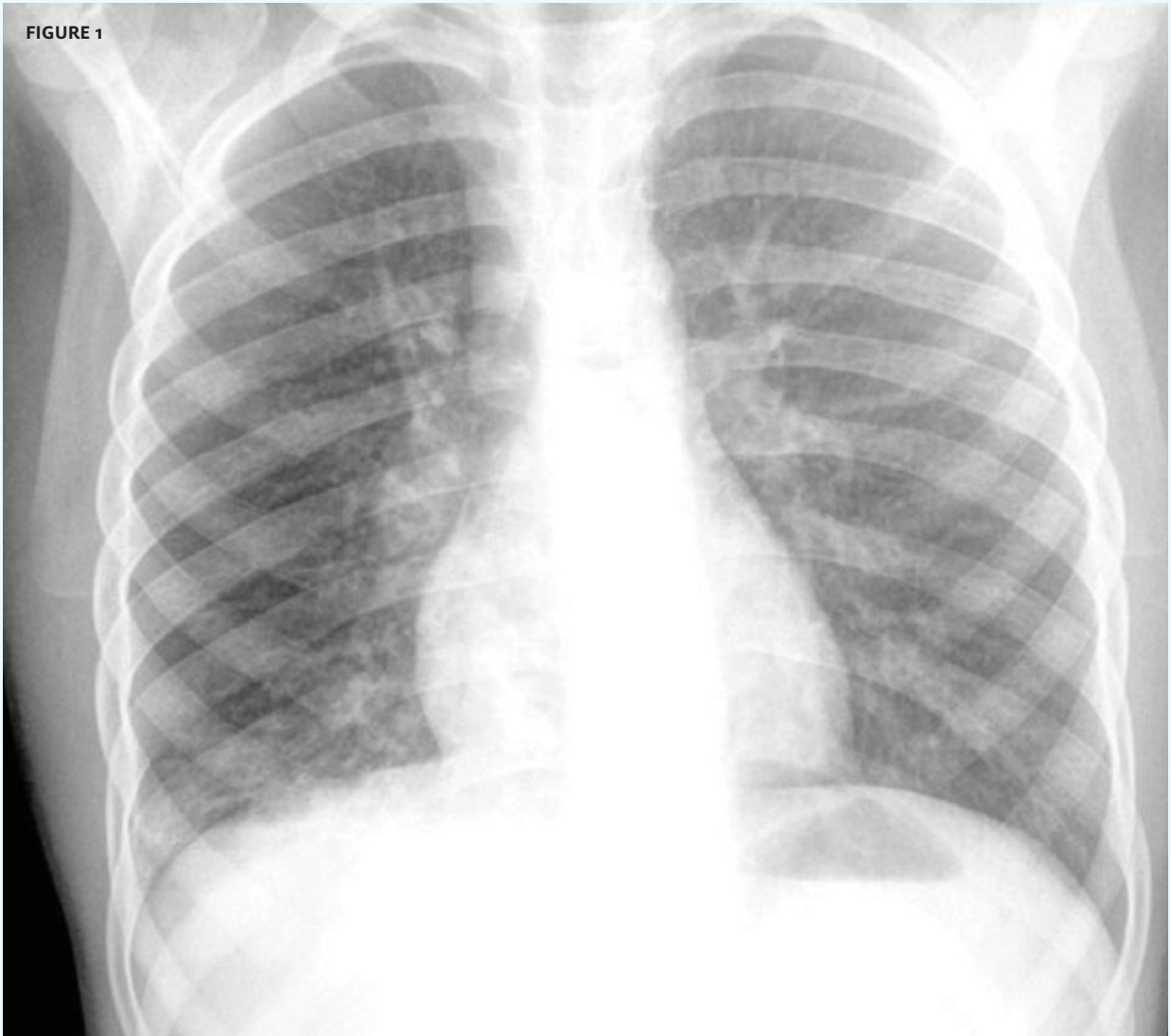




In each issue, *JUCM* will challenge your diagnostic acumen with a glimpse of x-rays, electrocardiograms, and photographs of dermatologic conditions that real urgent care patients have presented with.

If you would like to submit a case for consideration, please email the relevant materials and presenting information to [editor@jucom.com](mailto:editor@jucom.com).

FIGURE 1



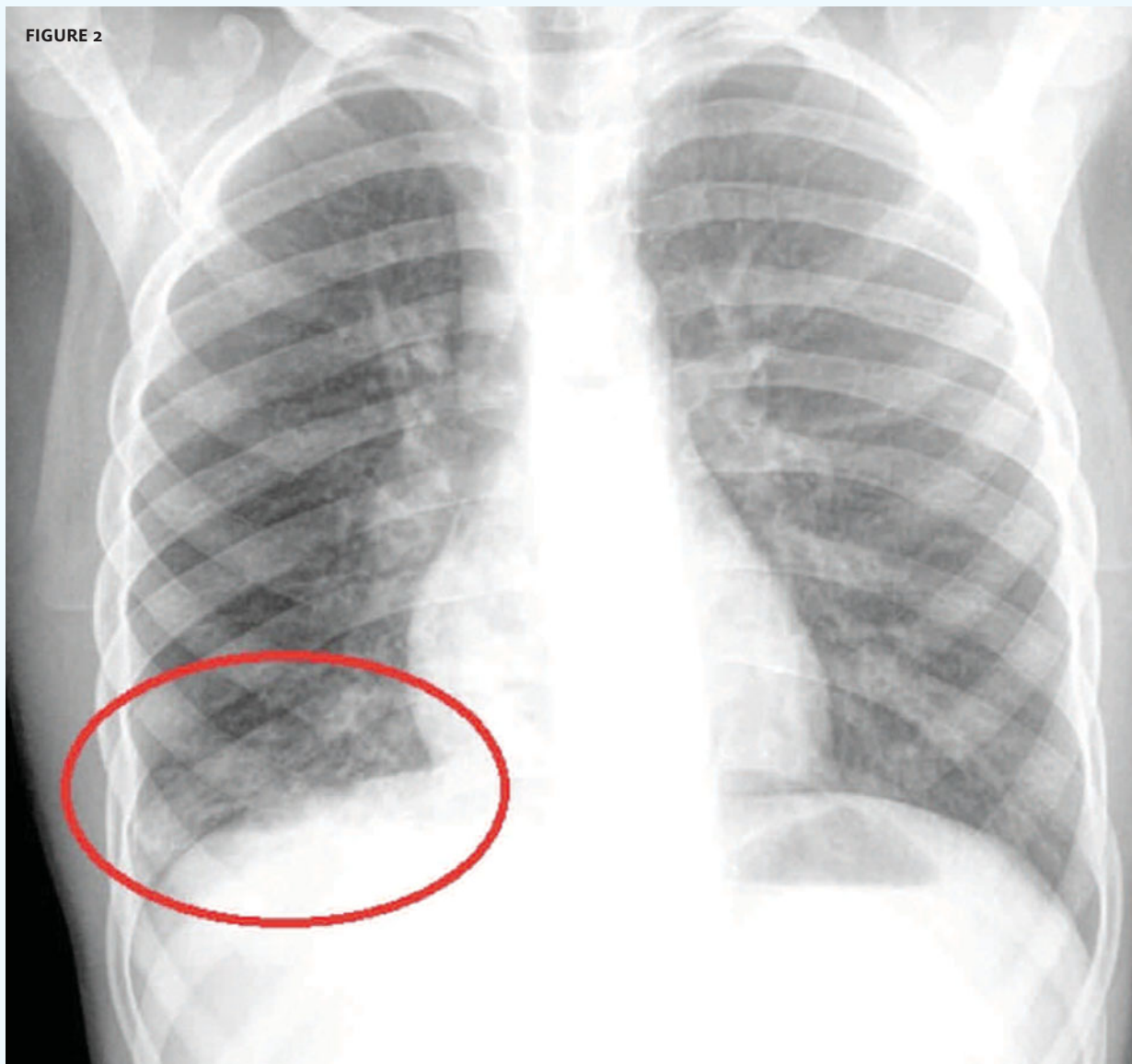
The patient, an 8-year-old male, presented with a cough and fever.

View the image taken (**Figure 1**) and consider what your diagnosis would be.

Resolution of the case is described on the next page.

THE RESOLUTION

FIGURE 2

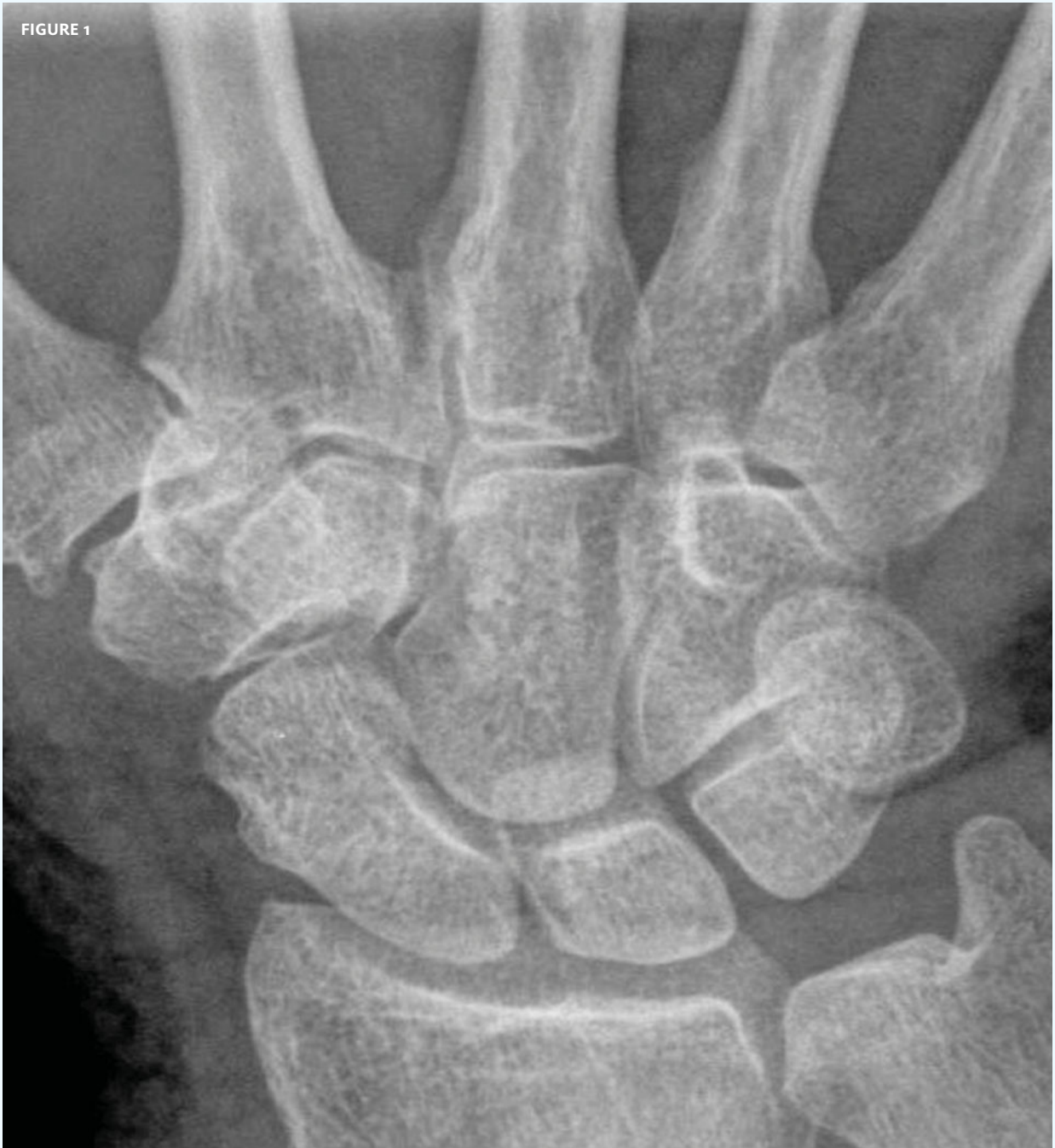

Diagnosis: The x-ray reveals infiltrate in the right lower lobe of the lung (circle). This patient has pneumonia.

Acknowledgement: Case presented by Nahum Kovalski, BSc, MDCM, Terem Emergency Medical Centers, Jerusalem, Israel.



FIGURE 1



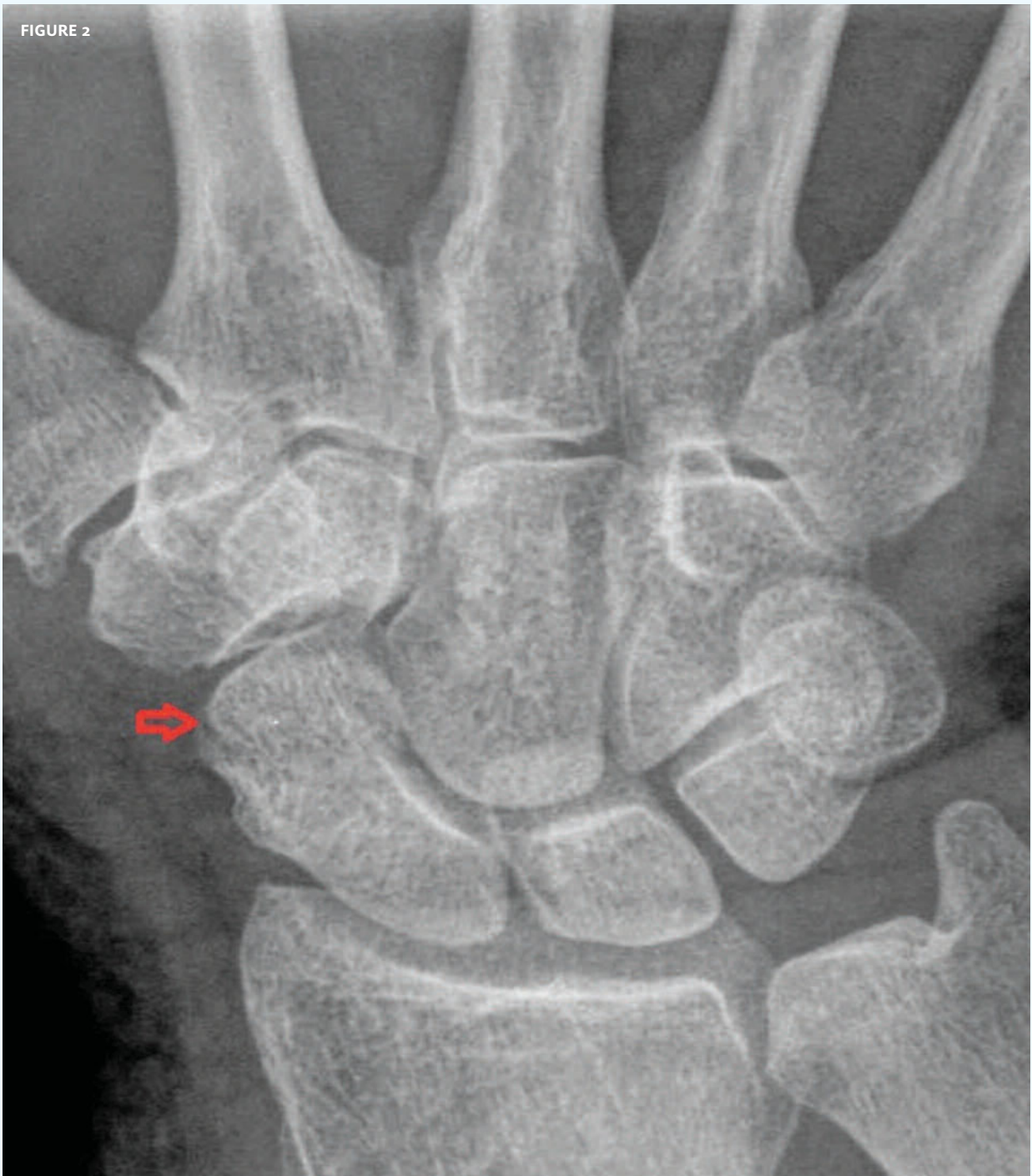The patient, a 76-year-old woman, presented with a blow to her right wrist.

View the image taken (**Figure 1**) and consider what your diagnosis would be.

Resolution of the case is described on the next page.

THE RESOLUTION

FIGURE 2



Diagnosis: The x-ray reveals a fracture of the scaphoid (arrow). A spica cast and follow up with an orthopedist are appropriate for this patient.

Acknowledgement: Case presented by Nahum Kovalski, BSc, MDCM, Terem Emergency Medical Centers, Jerusalem, Israel.