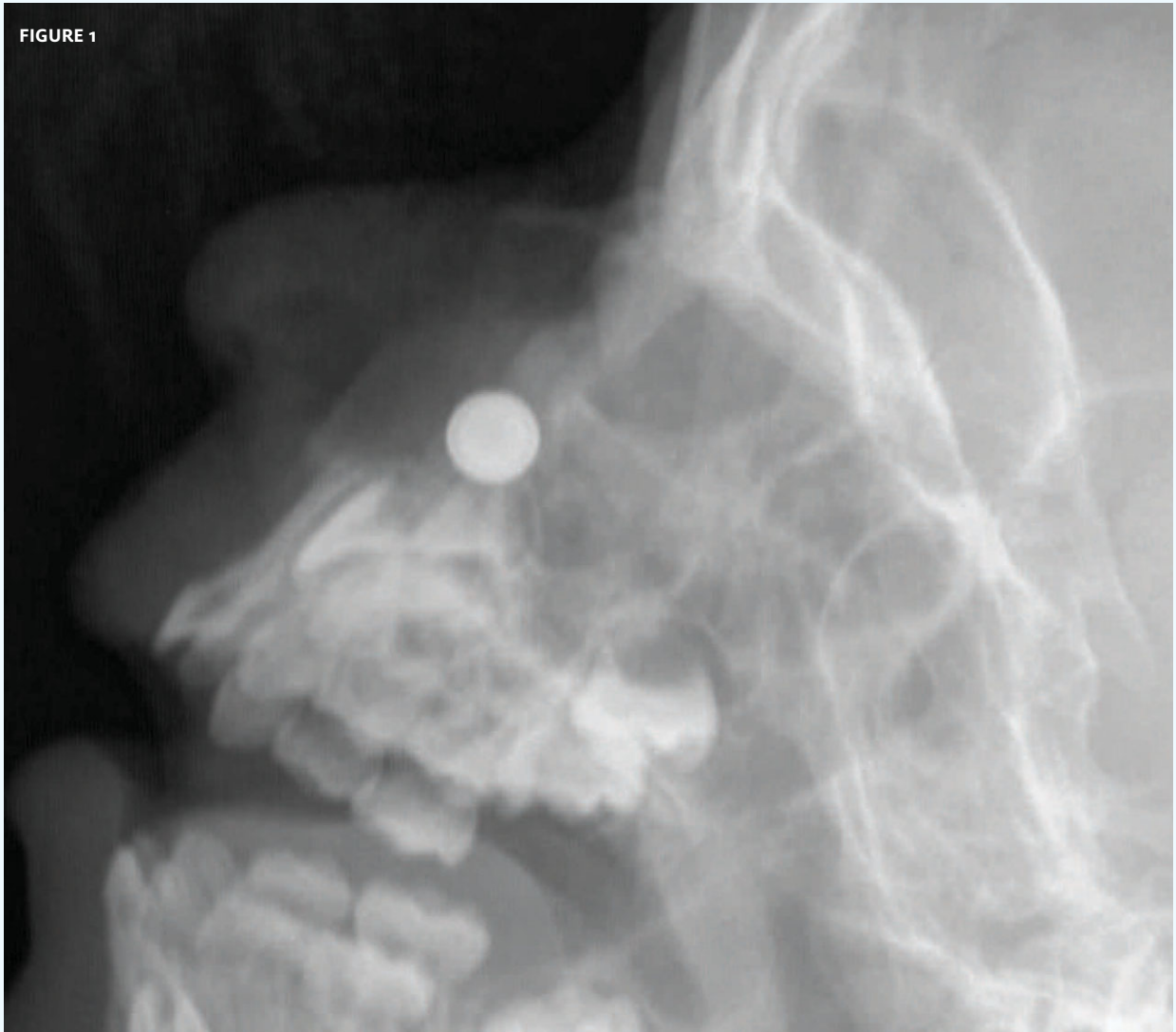




In each issue, *JUCM* will challenge your diagnostic acumen with a glimpse of x-rays, electrocardiograms, and photographs of dermatologic conditions that real urgent care patients have presented with.

If you would like to submit a case for consideration, please email the relevant materials and presenting information to editor@jucom.com.

FIGURE 1



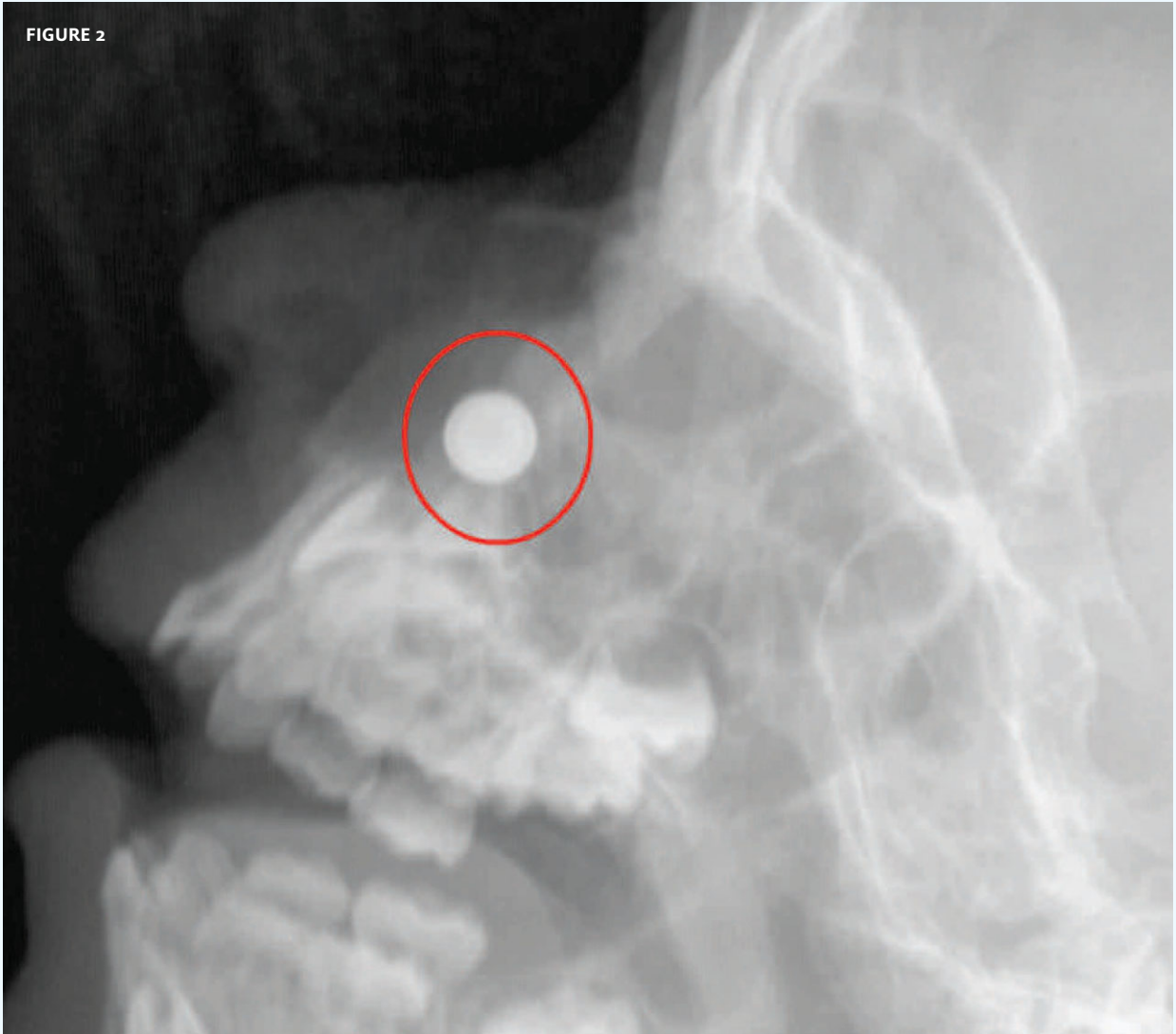
The patient, an otherwise healthy 2-year-old, had a history of playing with button batteries and then started crying with discomfort on the left side of the nose.

View the image taken (**Figure 1**) and consider what your diagnosis would be.

Resolution of the case is described on the next page.

THE RESOLUTION

FIGURE 2

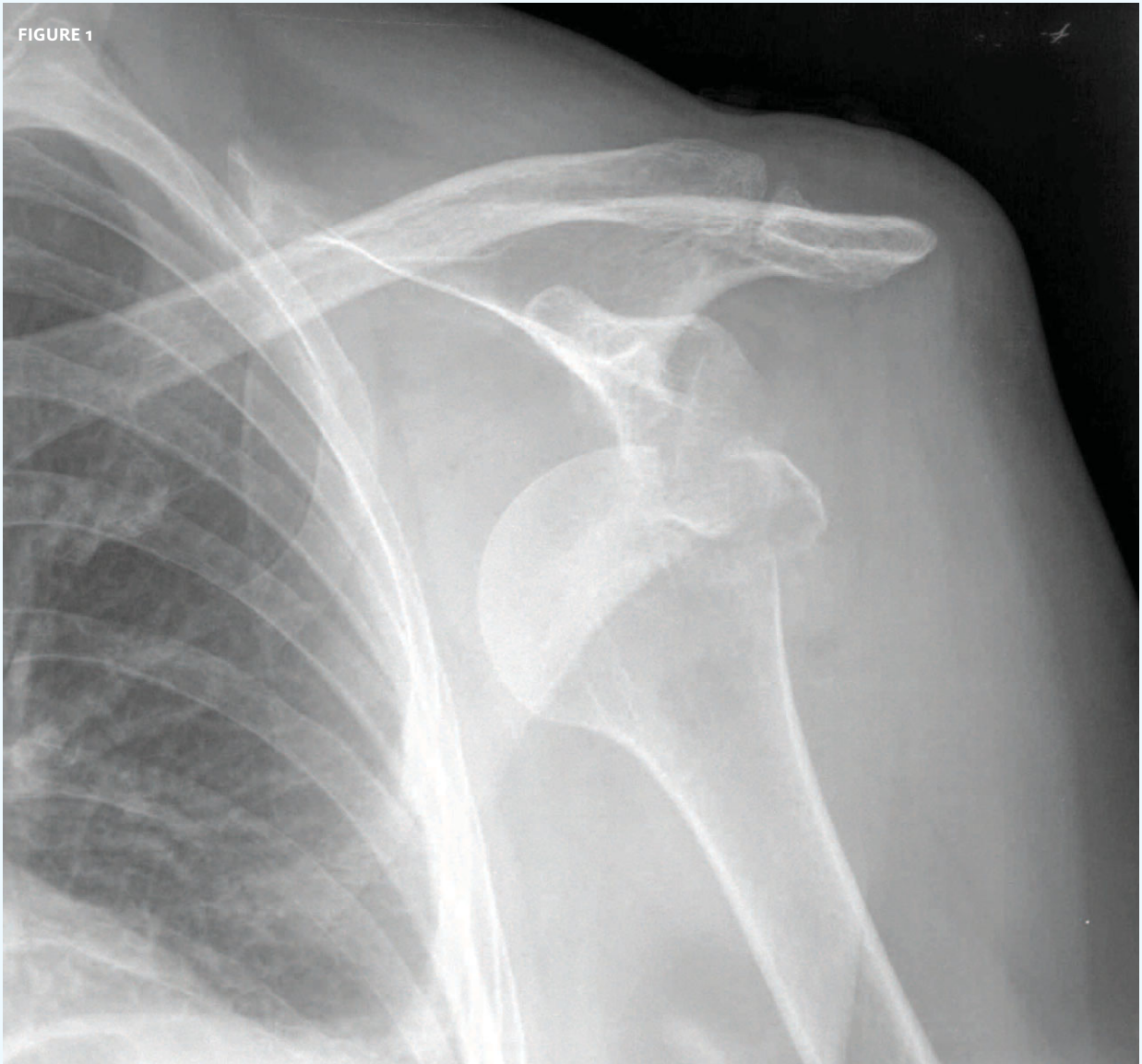


Diagnosis: button battery up the nasopharynx. Button batteries can cause devastating caustic injury to the nasal cavity and sinuses. Careful examination and x-ray/CT are critical when evaluating the possibility of this foreign body. Strong index of suspicion is necessary for toddlers presenting with unexplained bloody nose and irritability, as this can often be the only sign in this age group.

Acknowledgement: Case presented by Nahum Kovalski, BSc, MDCM, Terem Emergency Medical Centers, Jerusalem, Israel.



FIGURE 1

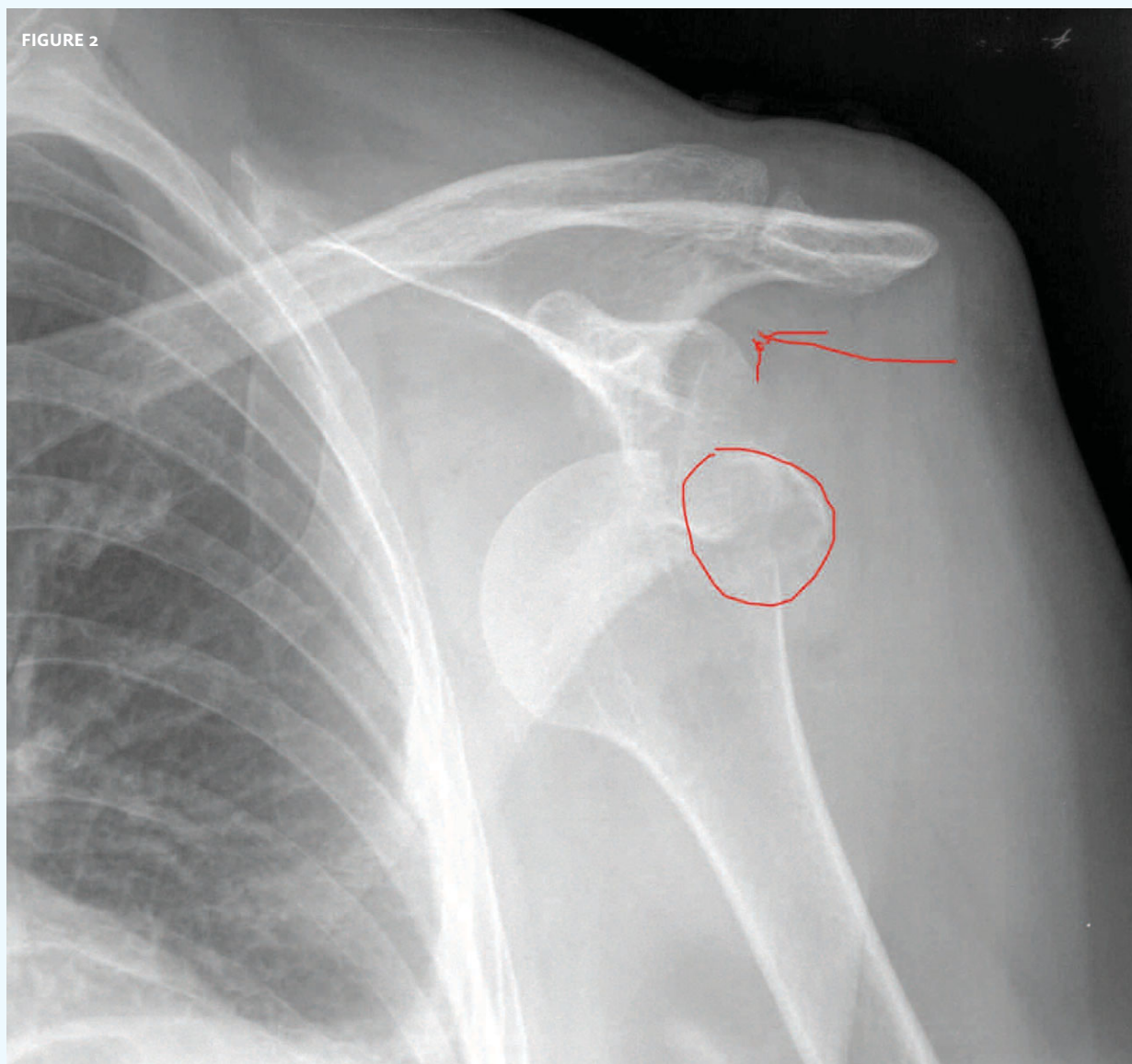


The patient, an otherwise healthy 64-year-old, fell, suffered a blow to the shoulder, and presents with clinical dislocation.

View the image taken (**Figure 1**) and consider what your diagnosis would be.

Resolution of the case is described on the next page.

THE RESOLUTION



Dislocation of the head of the humerus is evident but there is also a fracture. This is one of the reasons it is so important to get a pre-reduction film even in classical dislocation. Fractures can complicate reductions. They can “catch” on surrounding anatomy and make reduction more difficult.

Acknowledgement: Case presented by Nahum Kovalski, BSc, MDCM, Terem Emergency Medical Centers, Jerusalem, Israel.