

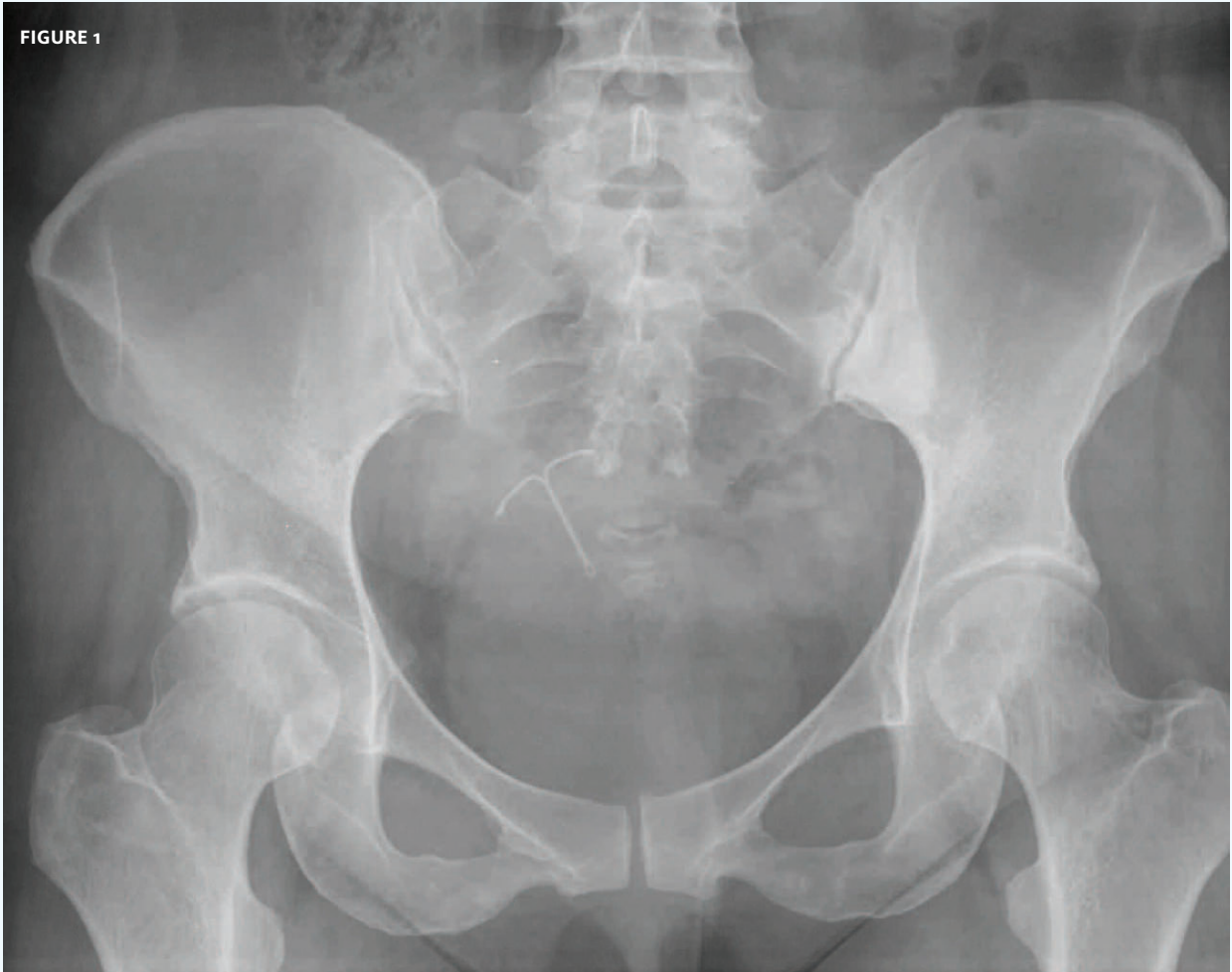


INSIGHTS IN IMAGE
CLINICAL CHALLENGE

In each issue, *JUCM* will challenge your diagnostic acumen with a glimpse of x-rays, electrocardiograms, and photographs of dermatologic conditions that real urgent care patients have presented with.

If you would like to submit a case for consideration, please email the relevant materials and presenting information to editor@jucm.com.

FIGURE 1



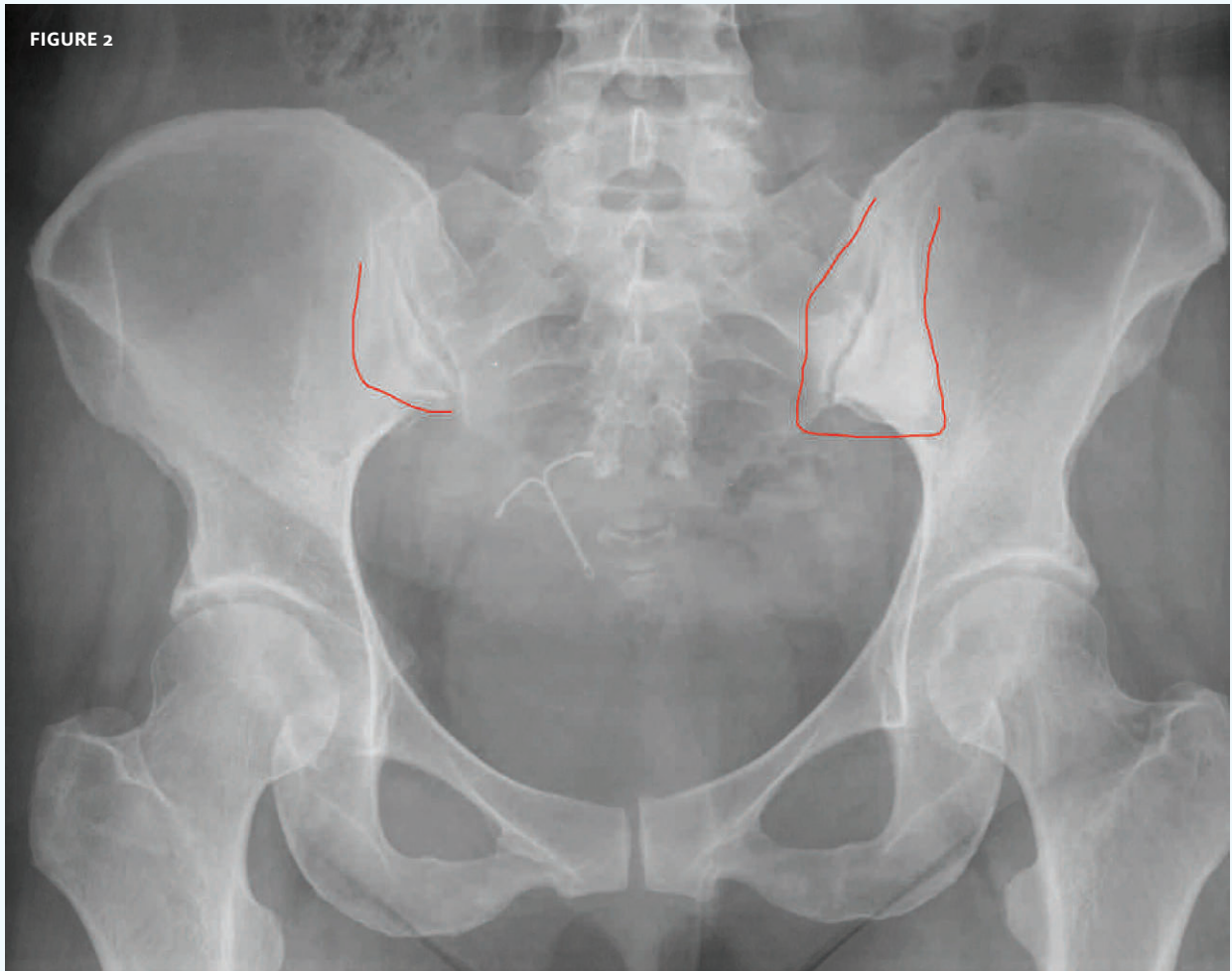
The patient, an otherwise-healthy 42-year-old, presented with bilateral back pain around the pelvis.

View the image taken (**Figure 1**) and consider what your diagnosis would be.

Resolution of the case is described on the next page.

THE RESOLUTION

FIGURE 2



Note: on the left, that is a sclerotic process along the right sacroiliac joint, and less so over the right. This is consistent with a sacroileitis.

Acknowledgement: Case presented by Nahum Kovalski, BSc, MDCM, Terem Emergency Medical Centers, Jerusalem, Israel.