

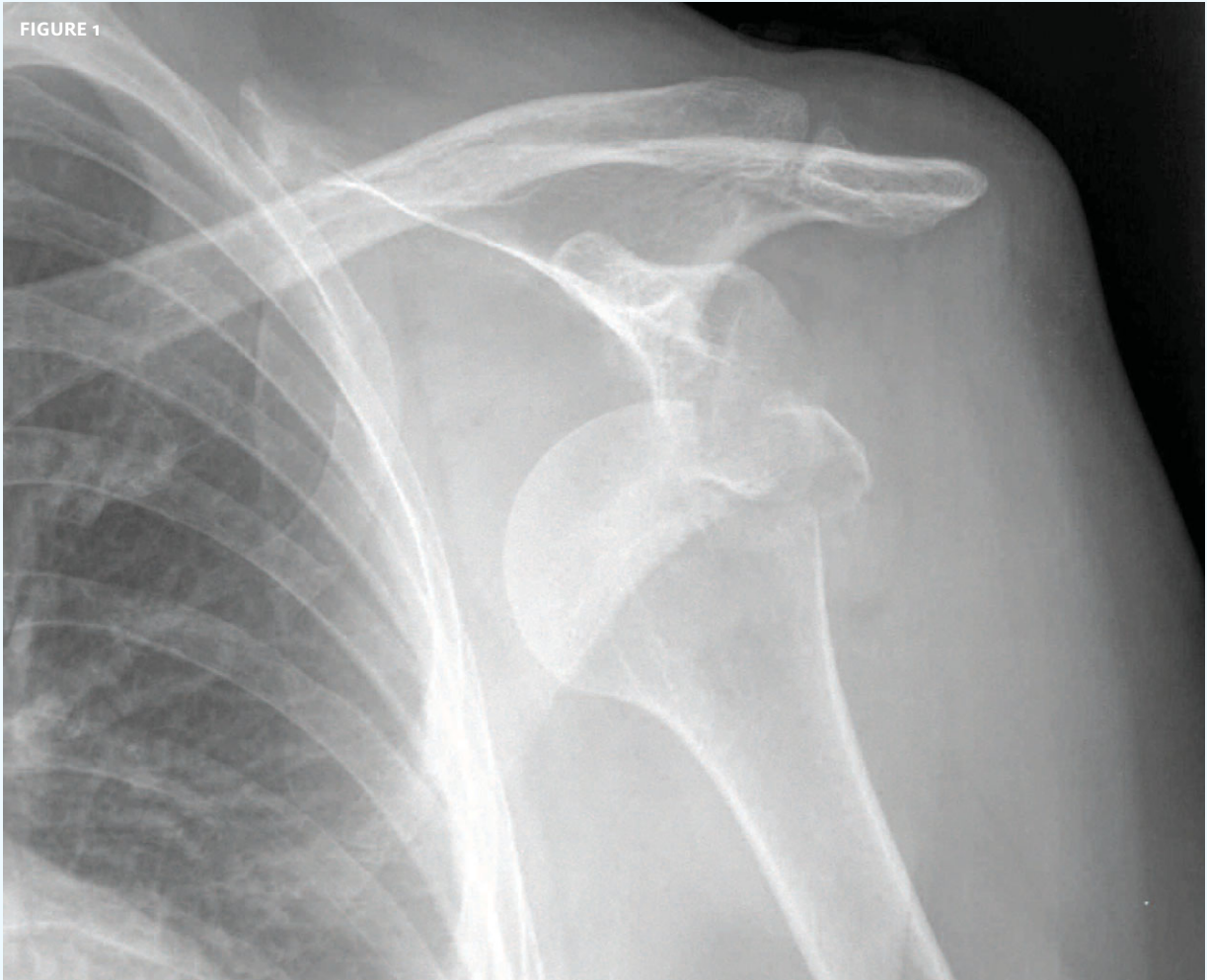

INSIGHTS IN IMAGE CLINICAL CHALLENGE

In each issue, *JUCM* will challenge your diagnostic acumen with a glimpse of x-rays, electrocardiograms, and photographs of dermatologic conditions that real urgent care patients have presented with.

If you would like to submit a case for consideration, please email the relevant materials and presenting information to editor@jucm.com.

FIGURE 1

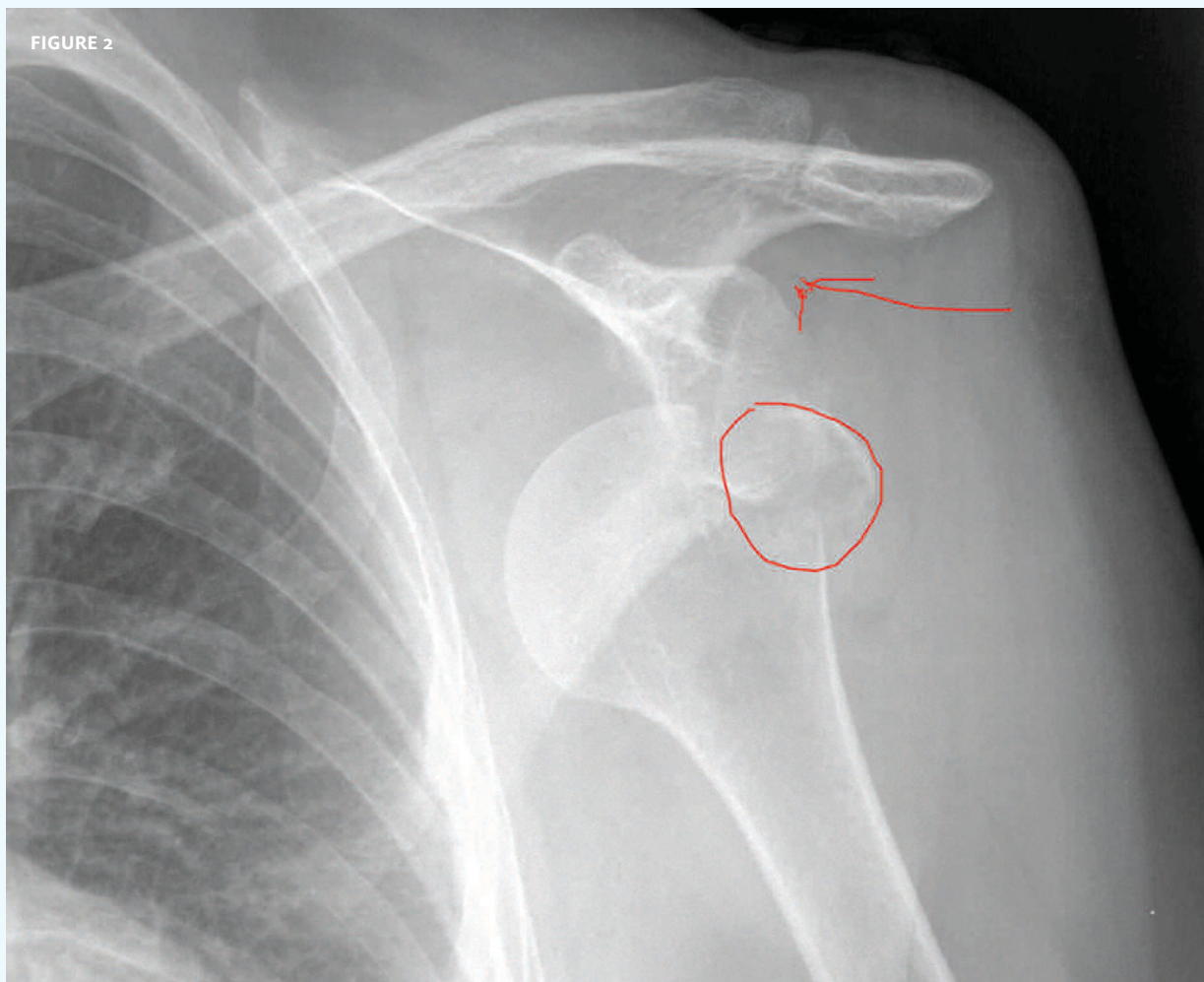


The patient is a 64-year-old man who presents with pain in his left shoulder after experiencing a fall in which the shoulder took the brunt of the blow. He is otherwise healthy.

View the image taken (**Figure 1**) and consider what your diagnosis and next steps would be.

Resolution of the case is described on the next page.

THE RESOLUTION



Dislocation of the head of the humerus is evident, but there is also a fracture.

This is one of the reasons it is so important to get a pre-reduction film, even in classical dislocation. Fractures can complicate reductions, as they can “catch” on surrounding anatomy.

Suspicion for fracture should be raised by the age of the patient, combined with the mechanism of injury. Where younger patients may be more prone to dislocation resulting from a fall on the outstretched arm, older patients are prone to fracture (with or without dislocation).

Acknowledgment: Case presented by Nahum Kovalski, BSc, MDCM, Terem Emergency Medical Centers, Jerusalem, Israel.

This case is one of hundreds that can be found in Terem's online X-ray Teaching File, with more being added daily. Free access to the file is available at <https://www2.teremi.com/xrayteach/>. A no-cost, brief registration is required.