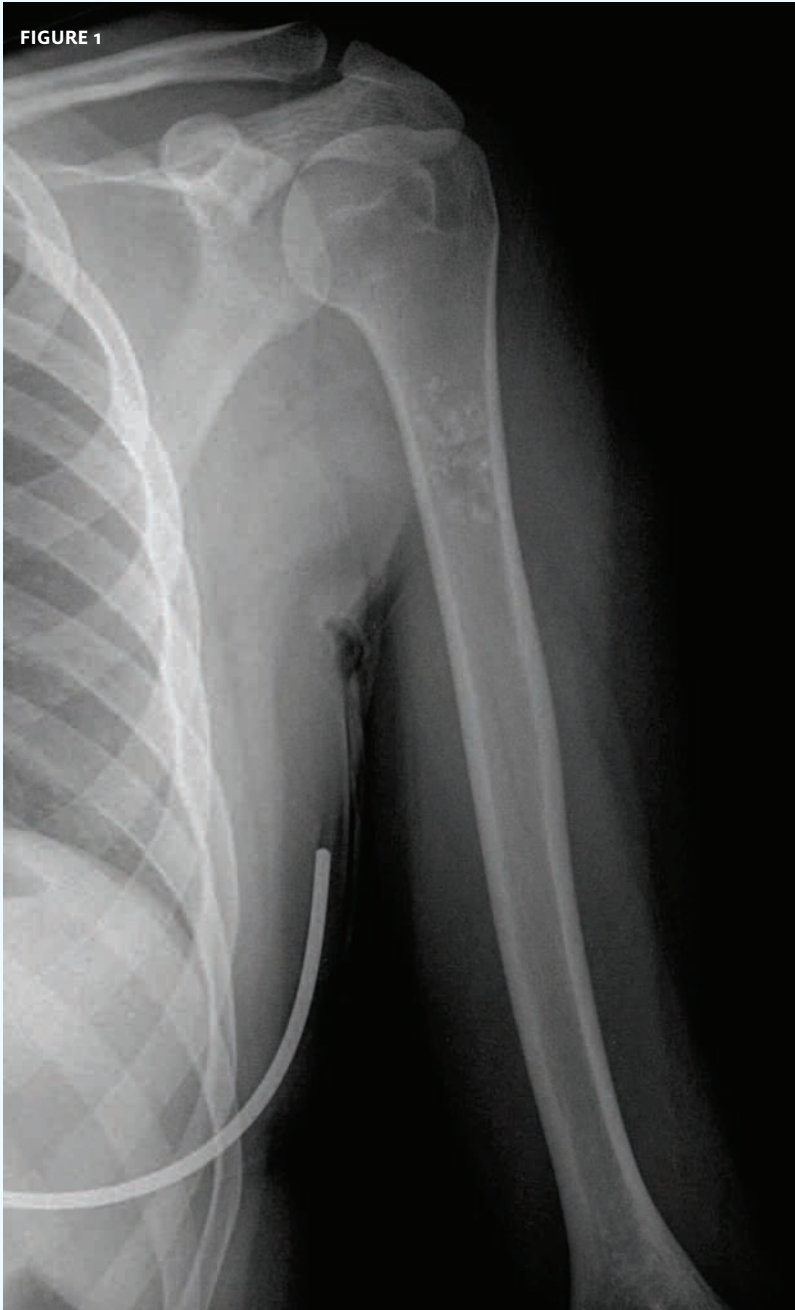




In each issue, *JUCM* will challenge your diagnostic acumen with a glimpse of x-rays, electrocardiograms, and photographs of dermatologic conditions that real urgent care patients have presented with.

If you would like to submit a case for consideration, please email the relevant materials and presenting information to editor@jucm.com.

FIGURE 1



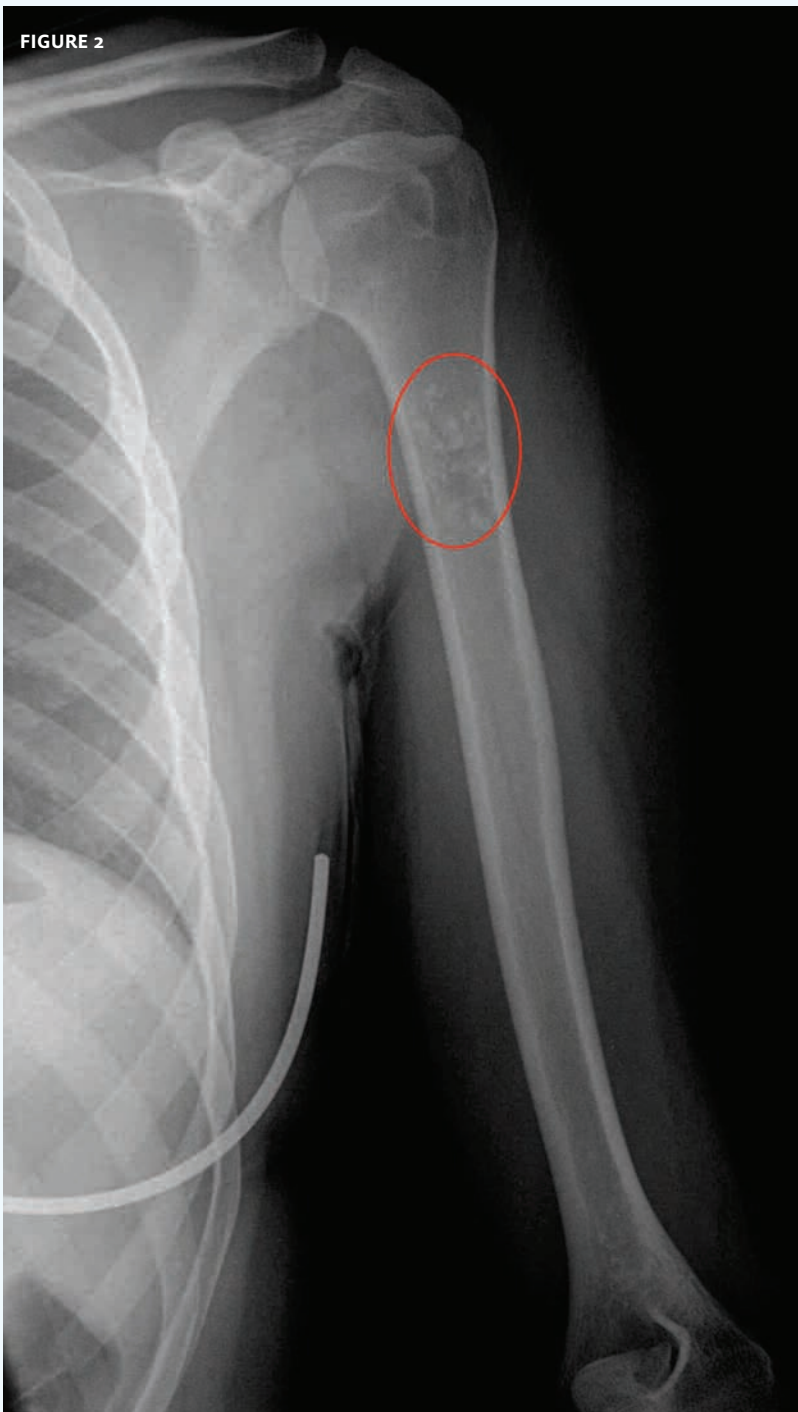
The patient, an otherwise healthy 18-year-old, presented with pain in the upper arm. There was no history of trauma.

View the image taken (**Figure 1**) and consider what your diagnosis and next steps would be.

Resolution of the case is described on the next page.

THE RESOLUTION

FIGURE 2



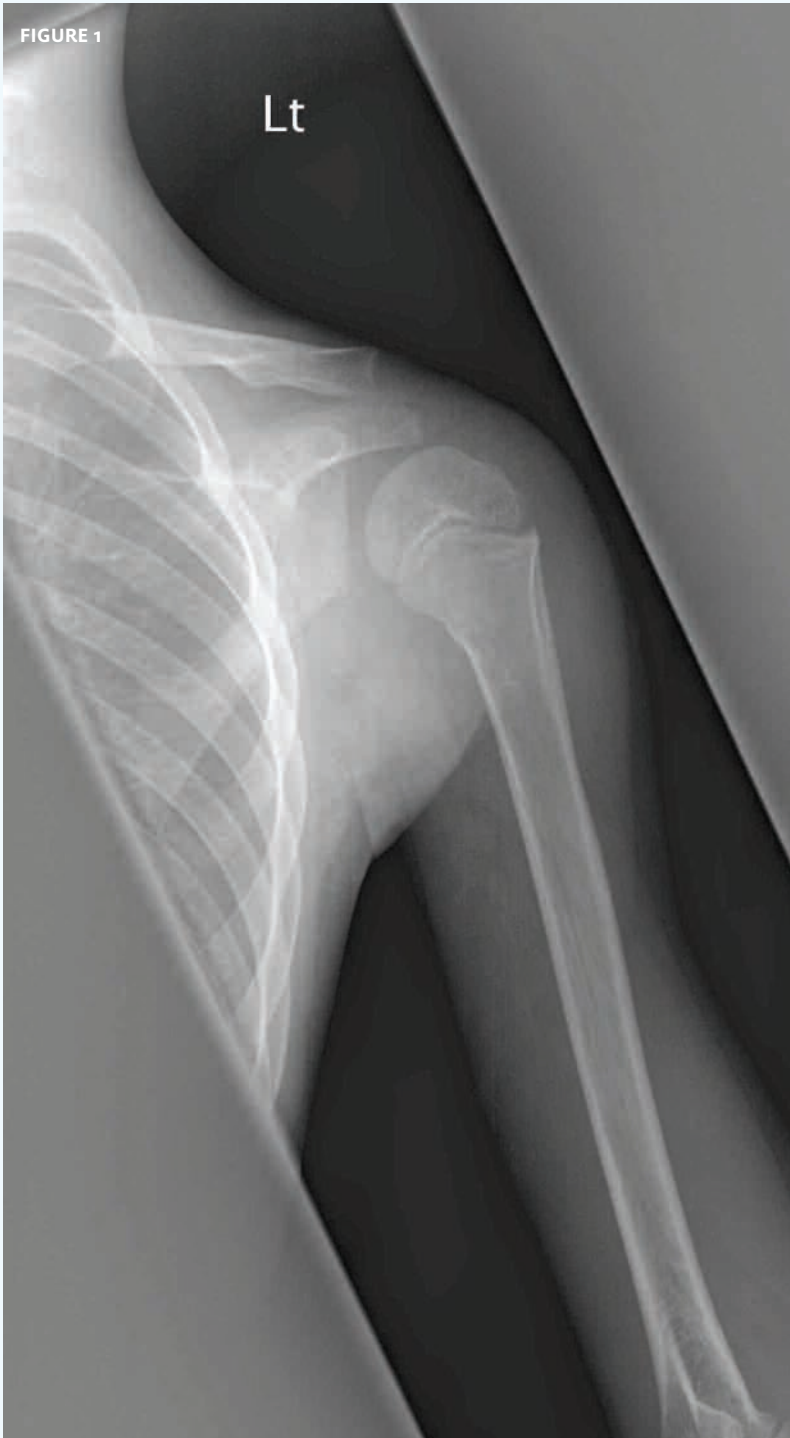There is a lesion in the upper humerus that is consistent with an osteoblastoma.

Next step: urgent orthopedic consultation.

Acknowledgement: Case presented by Nahum Kovalski, BSc, MDCM, Terem Emergency Medical Centers, Jerusalem, Israel.



FIGURE 1

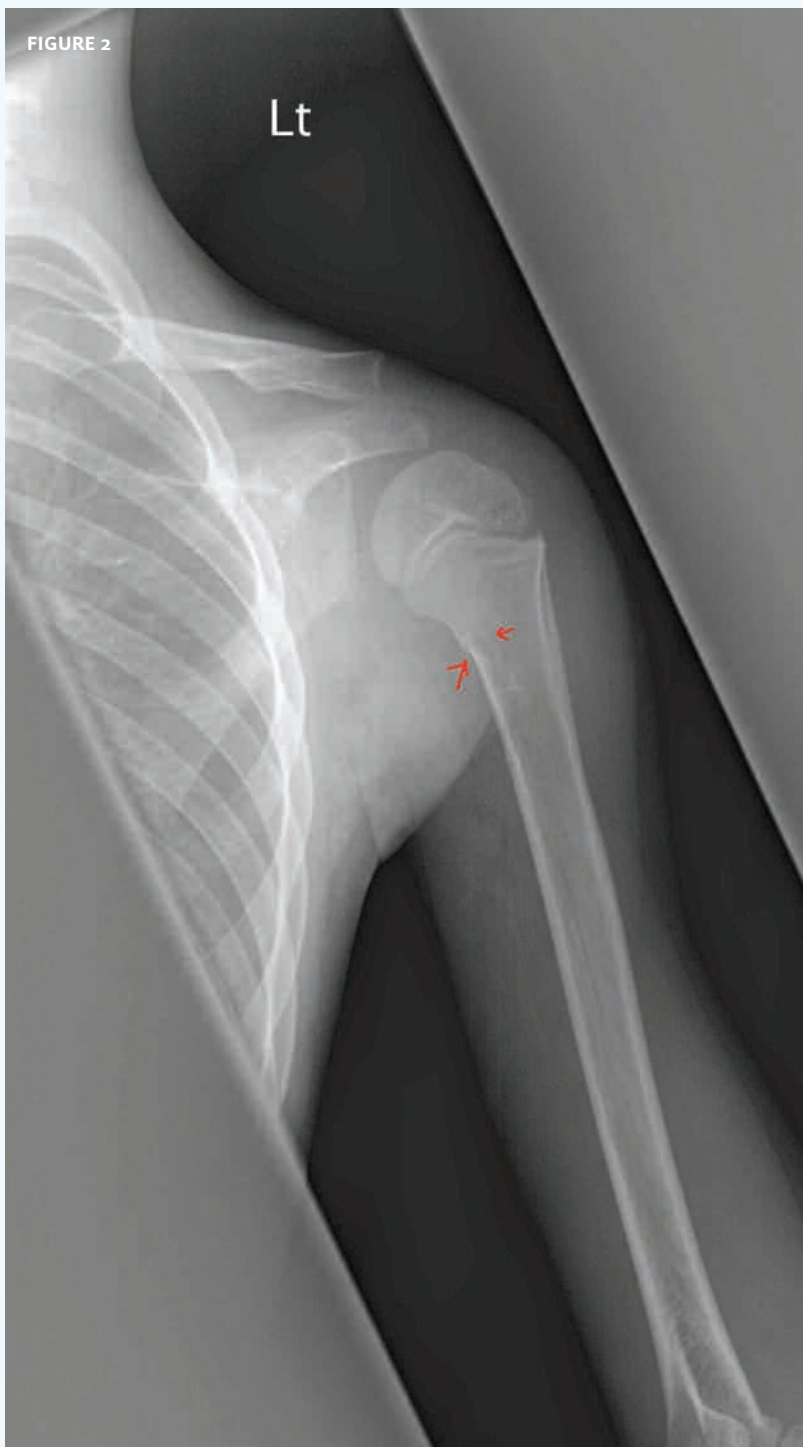

The patient, an otherwise healthy 10-year-old, fell and suffered a blow to the shoulder. The patient presented with a decreased range of motion.

View the image taken (**Figure 1**) and consider what your diagnosis and next steps would be.

Resolution of the case is described on the next page.

THE RESOLUTION



The patient has a greenstick fracture of the proximal humerus.

Next steps: sling and pain control.

Acknowledgement: Case presented by Nahum Kovalski, BSc, MDCM, Terem Emergency Medical Centers, Jerusalem, Israel.