



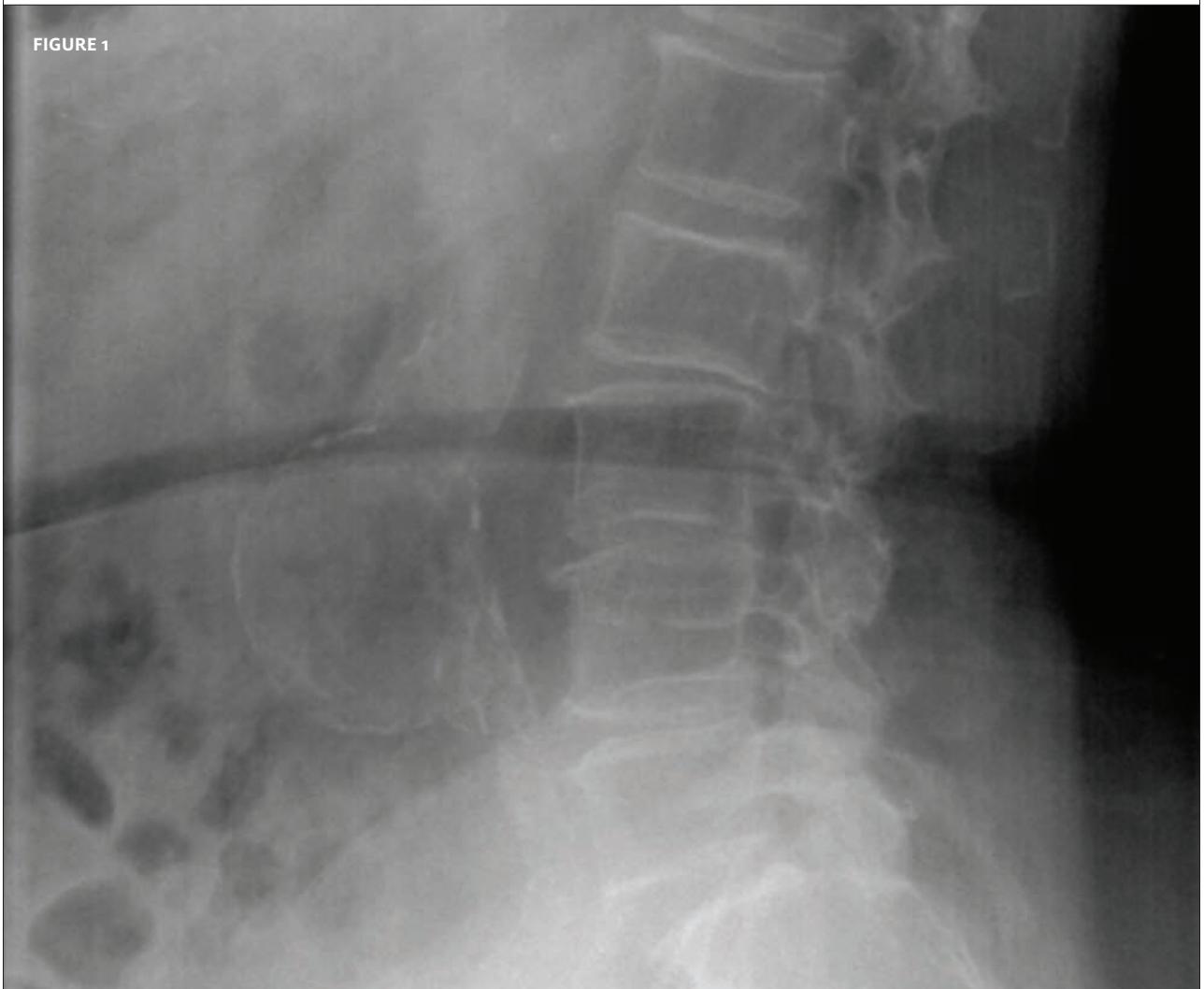
INSIGHTS IN IMAGES

CLINICAL CHALLENGE

In each issue, *JUCM* will challenge your diagnostic acumen with a glimpse of x-rays, electrocardiograms, and photographs of dermatologic conditions that real urgent care patients have presented with.

If you would like to submit a case for consideration, please e-mail the relevant materials and presenting information to editor@jucm.com.

FIGURE 1



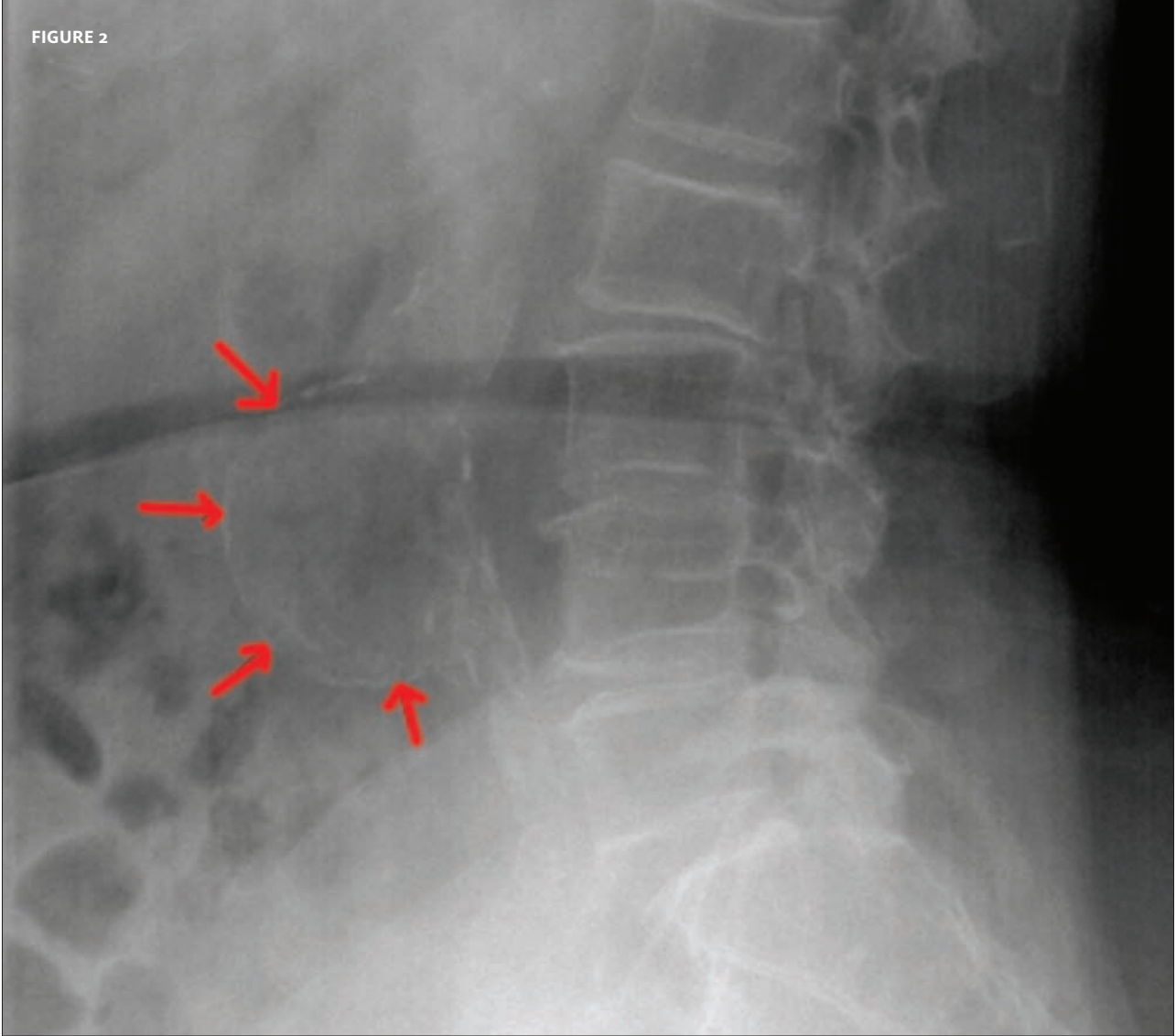
The patient is an 80-year-old man who presents to urgent care with low back pain of two weeks duration. He is hemodynamically stable and has a normal neurological exam. His personal medical history reveals hypertension, for which he is being treated.

Blood pressure is 140/80, pulse 63.

View the x-ray taken (**Figure 1**) and consider what your diagnosis and next steps would be. Resolution of the case is described on the next page.

THE RESOLUTION

FIGURE 2



The correct diagnosis is aortic aneurysm—which the patient acknowledged already being aware of, and for which he said he was under the observation of a vascular surgeon.

The urgent care clinician’s opinion was that the back pain was not related to the aneurysm. The patient was discharged for follow-up, despite the considerable concerns of clinical staff. However, the patient was insistent that this was a known condition and that he did not want immediate hospitalization.

A post-script: The aneurysm was measured at 6 cm x 7.5 cm, which is definitely sufficient to consider surgery.

Acknowledgment: Case presented by Nahum Kovalski, BSc, MDCM.