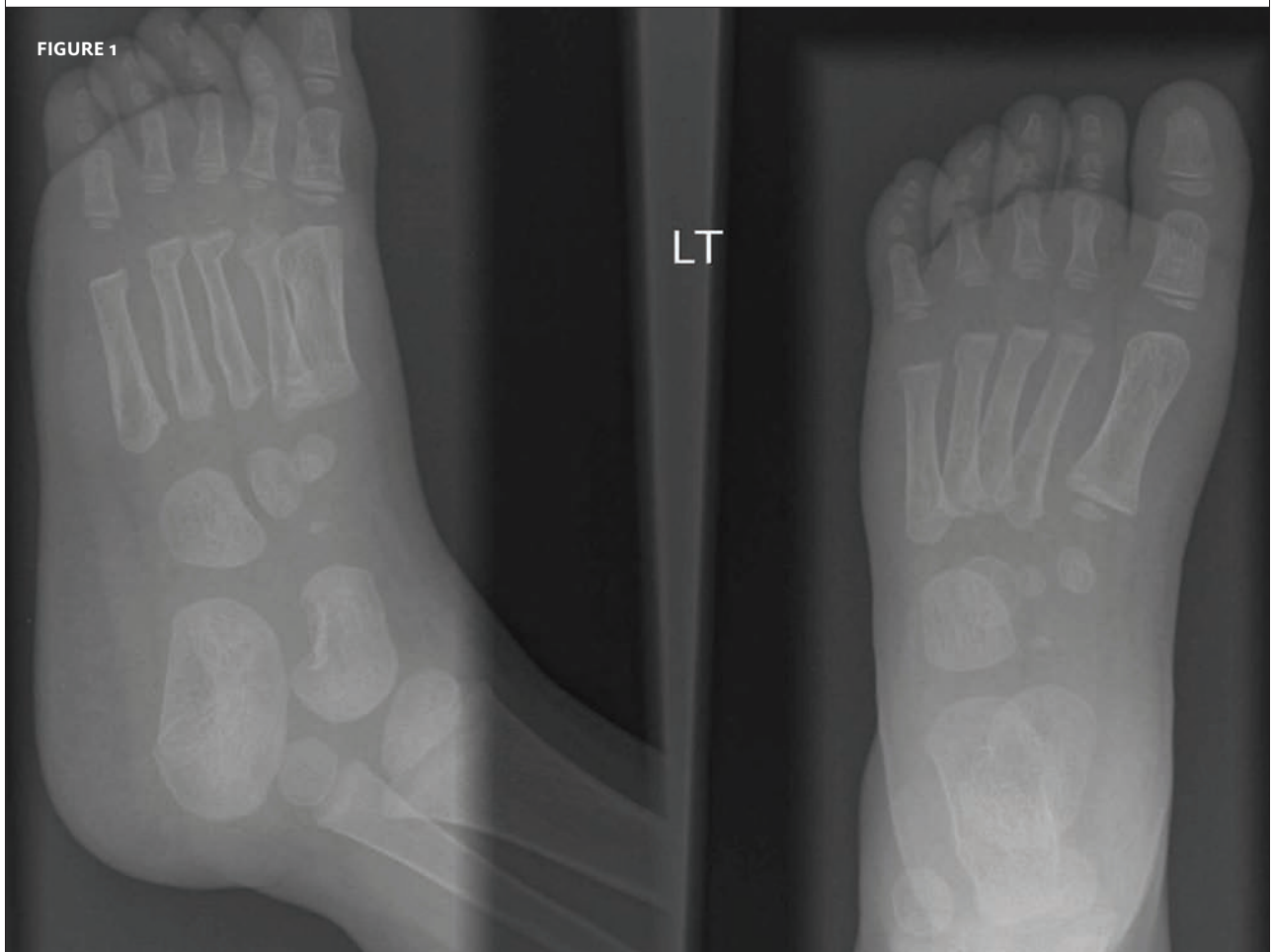




CLINICAL CHALLENGE: CASE 1

In each issue, *JUCM* will challenge your diagnostic acumen with a glimpse of x-rays, electrocardiograms, and photographs of dermatologic conditions that real urgent care patients have presented with.

If you would like to submit a case for consideration, please e-mail the relevant materials and presenting information to editor@jucm.com.



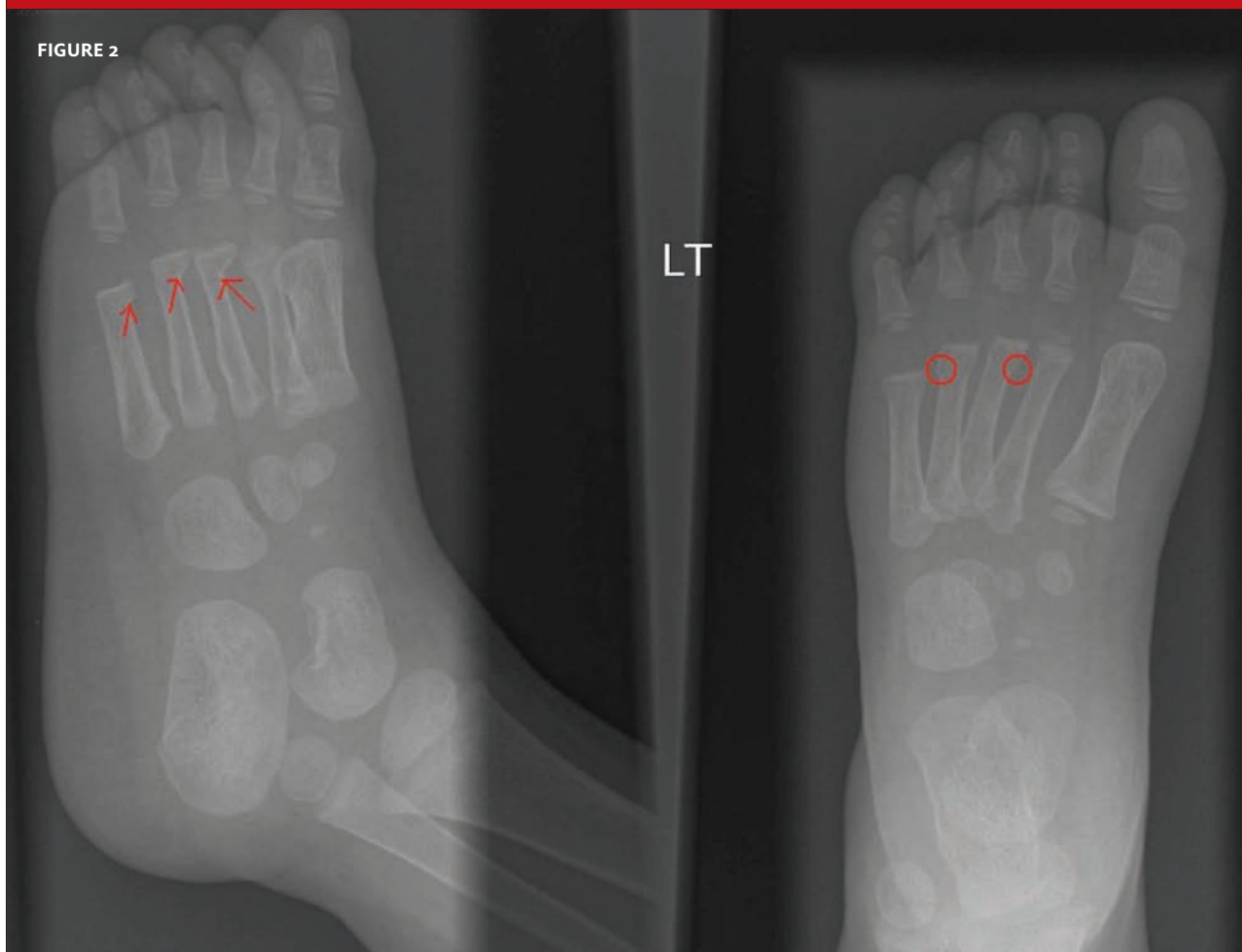The patient is a 2-year-old girl who experienced a blow to the left foot when she jumped from an unspecified height while playing. The parents were unaware at the time the injury occurred, but toward evening the girl refused to apply weight to her left foot.

On exam, the foot is mildly swollen and tender. Otherwise, there are no remarkable findings.

View the x-ray taken (**Figure 1**) and consider what your diagnosis and next steps would be. Resolution of the case is described on the next page.

THE RESOLUTION

FIGURE 2



The correct read of the x-ray is fracture of the third, fourth, and fifth metatarsals.

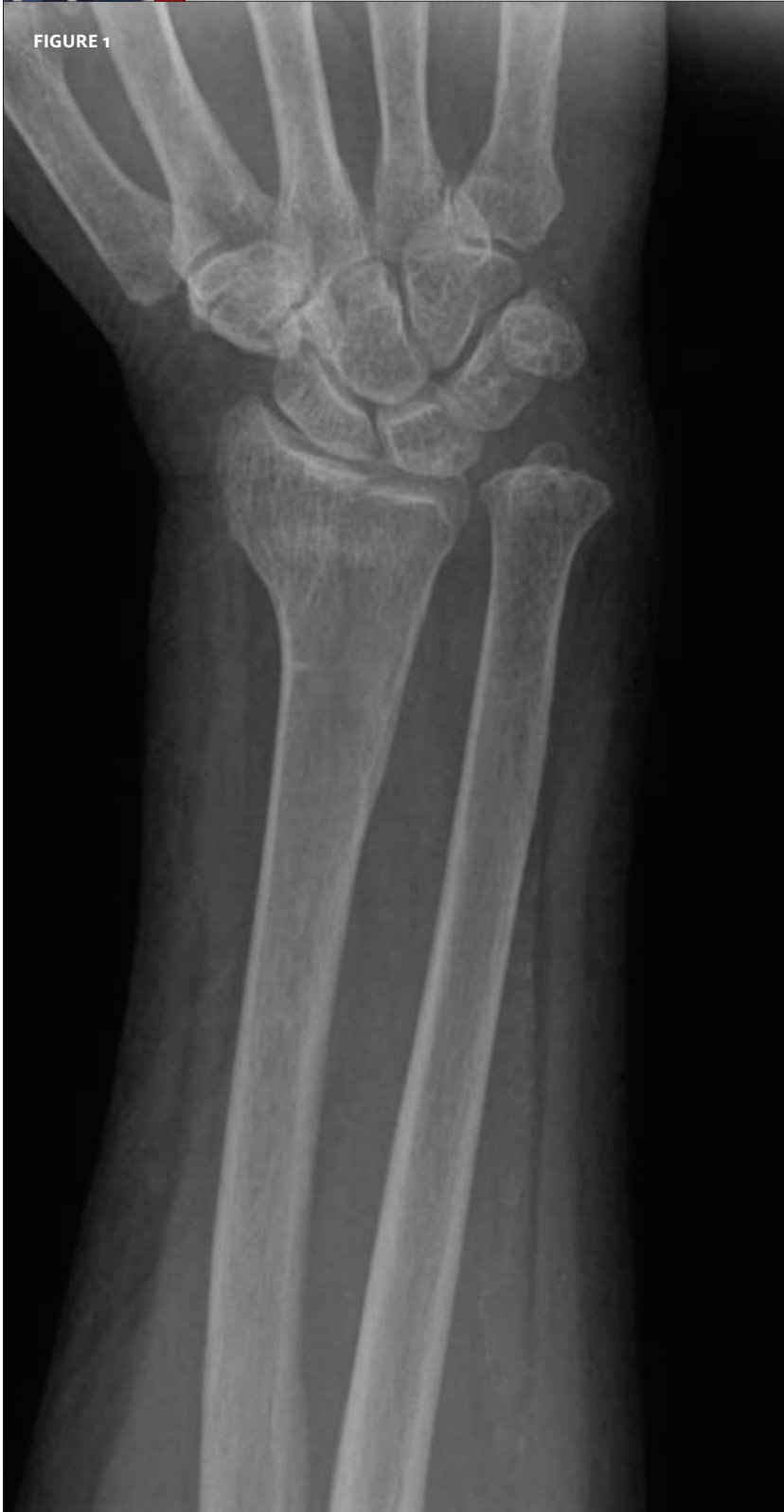The child was placed in a plaster splint, and the parents were advised to follow up with an orthopedist the next day.

Acknowledgment: Case presented by Nahum Kovalski, BSc, MDCM.



CLINICAL CHALLENGE: CASE 2

FIGURE 1



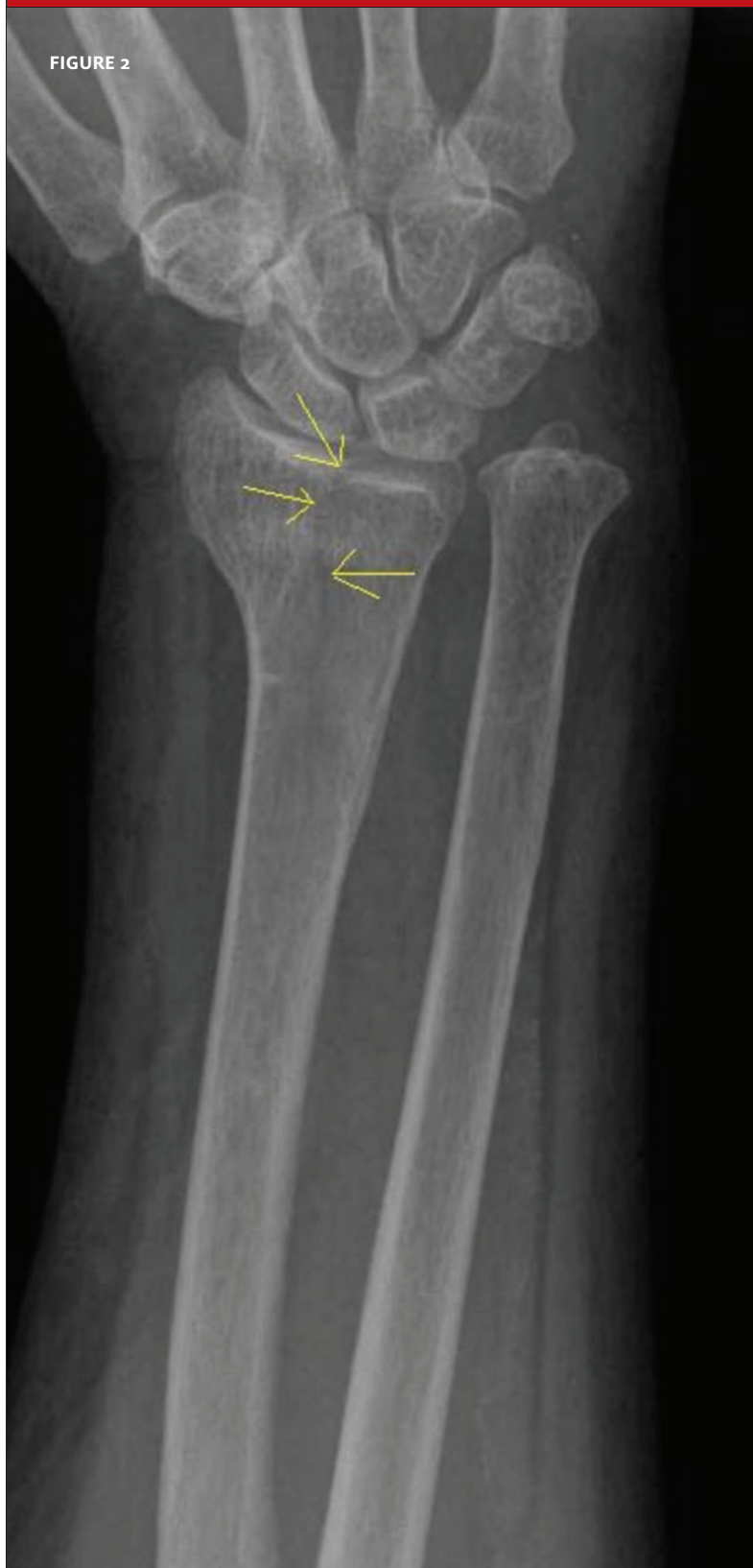The patient is a 73-year-old woman who presents with a foreign body (a piece of wood, specifically) sticking out of a scratch on her hand. She reports that she fell in her yard.

In addition, you discover that she has local pain and swelling of the left wrist.

View the x-ray taken (**Figure 1**) and consider what your diagnosis and next steps would be. Resolution of the case is described on the next page.

THE RESOLUTION

FIGURE 2



The correct diagnosis is an intra-articular fracture at the level of the wrist.

After removing the foreign body and providing a tetanus booster, she was referred for urgent orthopedic management.