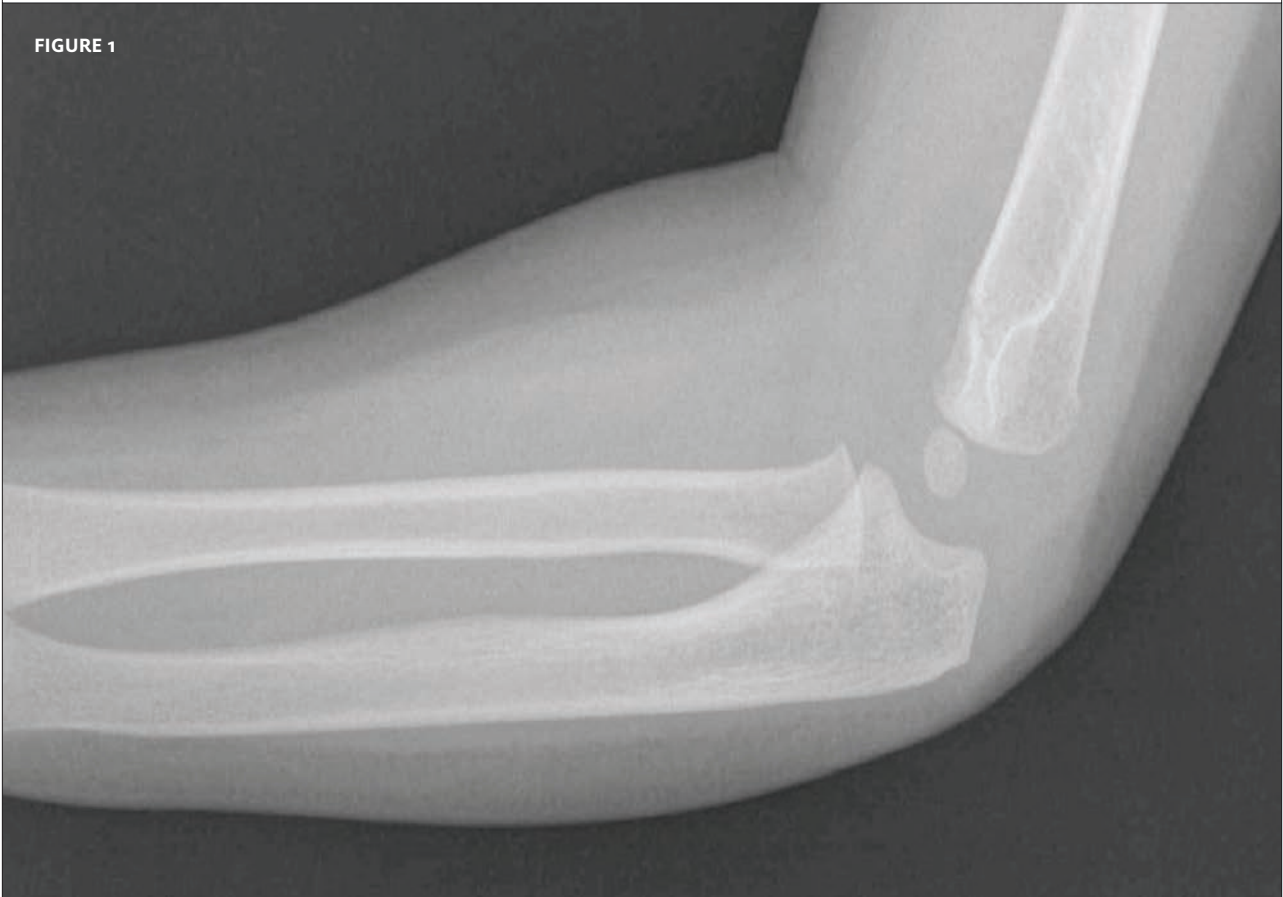



In each issue, *JUCM* will challenge your diagnostic acumen with a glimpse of x-rays, electrocardiograms, and photographs of dermatologic conditions that real urgent care patients have presented with.

If you would like to submit a case for consideration, please e-mail the relevant materials and presenting information to [editor@jucm.com](mailto:editor@jucm.com).

FIGURE 1



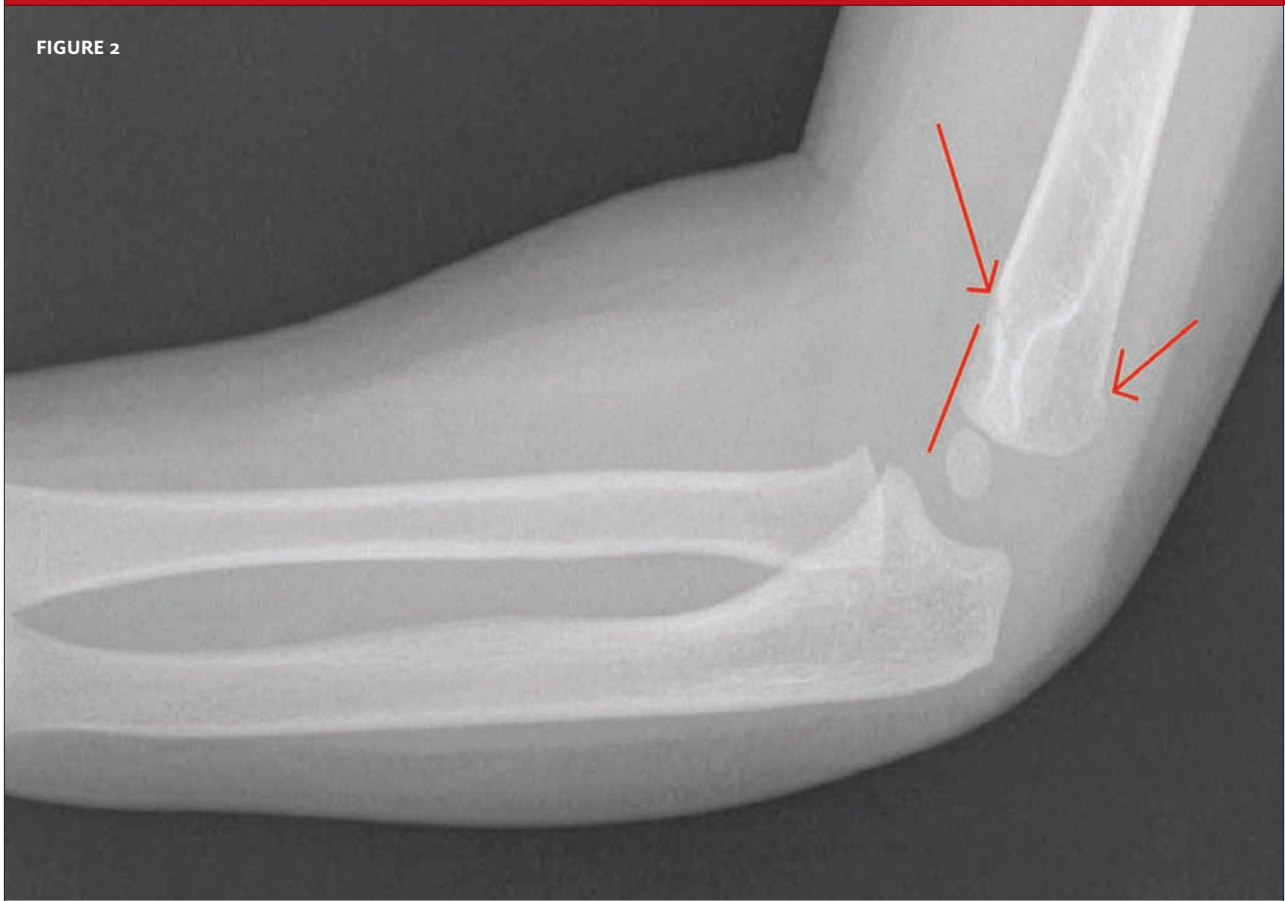The patient is a 2½-year-old female who presented after falling, unobserved, from an unknown height with tenderness and swelling around the elbow.

Neurovascular exam was normal.

View the x-ray taken (**Figure 1**) and consider what your diagnosis and next steps would be. Resolution of the case is described on the next page.

THE RESOLUTION

FIGURE 2



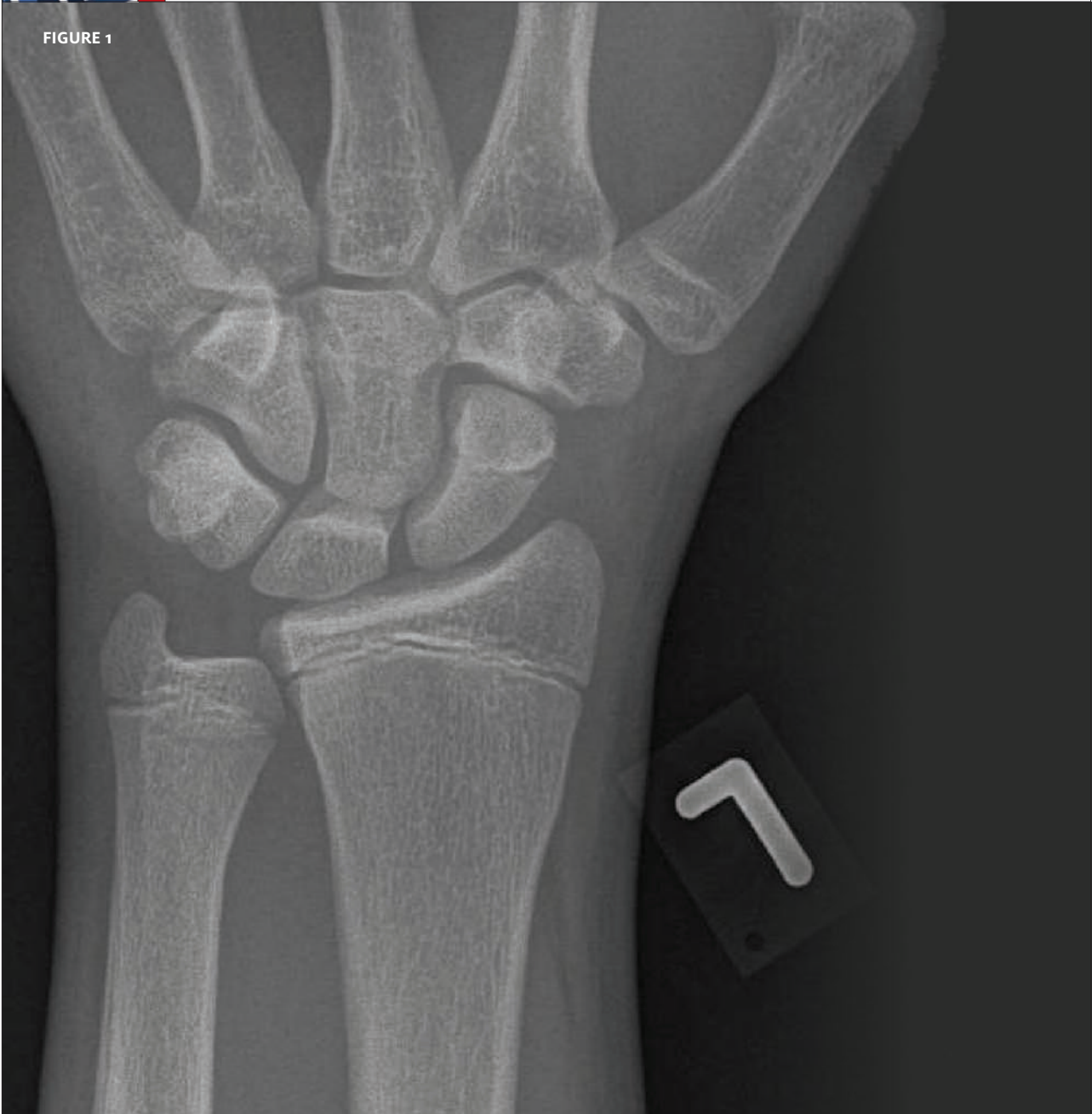The correct diagnosis is a supracondylar fracture; note the loss of the normal angle at the distal humerus.

The injury was managed with a posterior splint in flexion, with follow-up the next day with an orthopedist.

*Acknowledgment: Case presented by Nahum Kovalski, BSc, MDCM; the patient was treated by Dr. Elinor Vandermarva.*



FIGURE 1

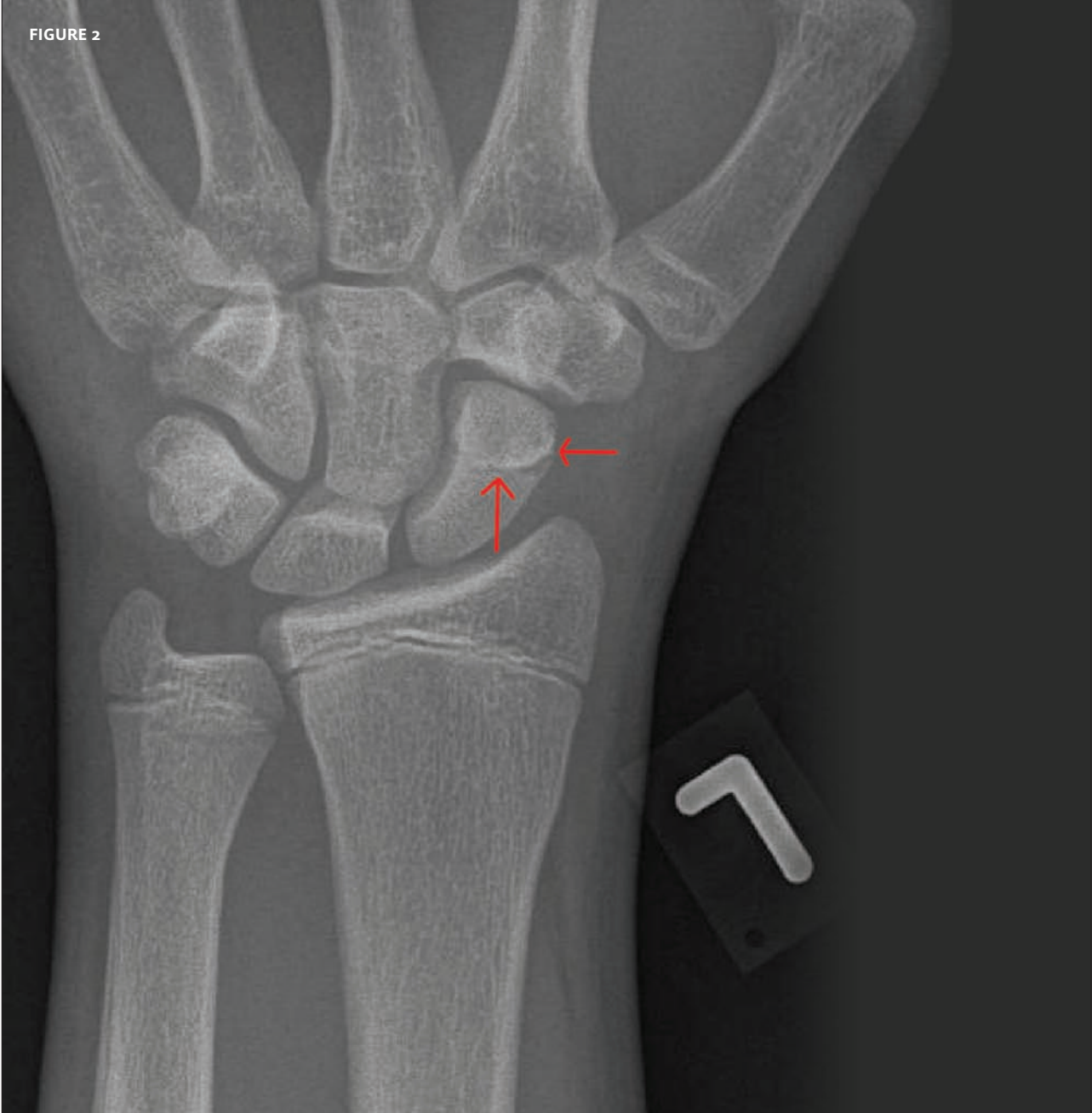


The patient is a 13-year-old male who presented to urgent care after taking a fall while running; he landed on his outstretched left hand. Upon examination, you find tenderness in the snuff box and observe swelling around the wrist.

View the x-ray taken (**Figure 1**) and consider what your diagnosis and next steps would be. Resolution of the case is described on the next page.

THE RESOLUTION

FIGURE 2



The patient experienced a scaphoid fracture. A spika case was applied, with follow-up with an orthopedist the following day.

*Acknowledgment: Case presented by Nahum Kovalski, BSc, MDCM; the patient was treated by Dr. Dan Frimerman.*